



# International Journal of Research Publication and Reviews

Journal homepage: [www.ijrpr.com](http://www.ijrpr.com) ISSN 2582-7421

## Homoeopathic Management of Chronic Eczema: A Case Report

<sup>1</sup> Dr. Pooja Sadashiv Kamble, <sup>2</sup> Dr. Sunil B. Banne, <sup>3</sup> Dr. Saroj R. Sawant

<sup>1</sup>M.D scholar, Department of homoeopathic materia medica, Dr. J.J. Magdum Homoeopathic medical college, Jaysingpur, Maharashtra, India

<sup>2</sup>HOD, PG Guide, Department of homoeopathic materia medica, Dr. J.J. Magdum Homoeopathic medical college, Jaysingpur, Maharashtra, India

<sup>3</sup>Professor, Department of homoeopathic materia medica, Dr. J.J. Magdum Homoeopathic medical college, Jaysingpur, Maharashtra, India

### ABSTRACT:

Eczema is a skin condition in which patches of skin becomes rough and inflamed with blisters which causes itching and bleeding. Causative factor may be internal (hormonal imbalance, stress, weakening of epidermal layer) and external (chemicals, skin care products etc ). there are various types of eczema which have similar symptoms and features but differs in cause and progression. conventional system of medicine has no specific cure for eczema. however, homoeopathy excels in having many systemic medicines useful in general as well as for specific type of eczema. In given case remedy was prescribed to an elderly woman with widespread vesicular eruption over both soles, itching, ruptures on scratching, burning with excessive sweating after individualization of case. A marked improvement in eczema as well as in mental condition is observed within short span of time. homoeopathic medicine selected on the basis of symptom similarity found to be having marked effectiveness in chronic eczema.

**KEYWORDS:** eczema, homoeopathy, merc sol.

### INTRODUCTION

Eczema is an inflammatory skin condition that causes itchiness, dry skin, rashes, scaly patches, blisters and skin infection. itchy skin is the most common symptom of eczema. symptoms of eczema often include: itch, dryness, sensitive skin; inflamed, discoloured skin; rough, leathery or scaly skin, appearing as scaly patches; oozing or crusting vesicles; areas of swelling (1). eczema is a relatively common cause of morbidity among the older population. It decreases the quality of life of affected persons and increases the cost of medical care (2). The global burden of skin disease study (2010) estimated that AD affects up to 230 million people worldwide (3) (4). In this regard nationwide, systemic studies identifying the disease burden, epidemiology, and challenges in the diagnosis and management of AD in India are lacking.

According to homoeopathic principles, external manifestation i.e. skin affection is reflection of internal systemic disease so, it should be treated with constitutionally to find out the exact cause of skin manifestation rather than suppressing it by local means can lead to more severe systemic problems, deepening of disease inward. Here a case of eczema is presented which is treated with individualised homoeopathic medicine, showing the effectiveness of homoeopathy in such cases.

### PATIENT INFORMATION

A 56 years old female, from a middle socio-economic status came to O.P.D of Dr. J.J. Magdum Homoeopathic medical college and hospital, Jaysingpur on 17 May 2024 with complaints of multiple painless vesicular eruption over both soles of feet, which gradually increase in size with itching, rupturing with exudation of fluids later on crusting to form scab. The patient has been suffering from complaint for 6-7 months.

The patient is k/c/o DM and HTN since 10 years. and no any major illness in family. h/o same lesion on hands and fingers 7 months ago.

The thermal reaction of the patient was ambithermal, aggravated by both extremes of temperature. The appetite of patient was decreased, the patient had a desire for tea, sweet and cold food, stool was regular, normal in consistency. The sleep of patient was disturbed for 7 months with anxiety at night with much sweating all over body. perspiration mostly on head.

The patient appeared secretive, slight hasty speech. The patient was anxious for her own health and about future. All symptoms were started after fear of money loss. The patient was headstrong, strong willed as described by relatives.

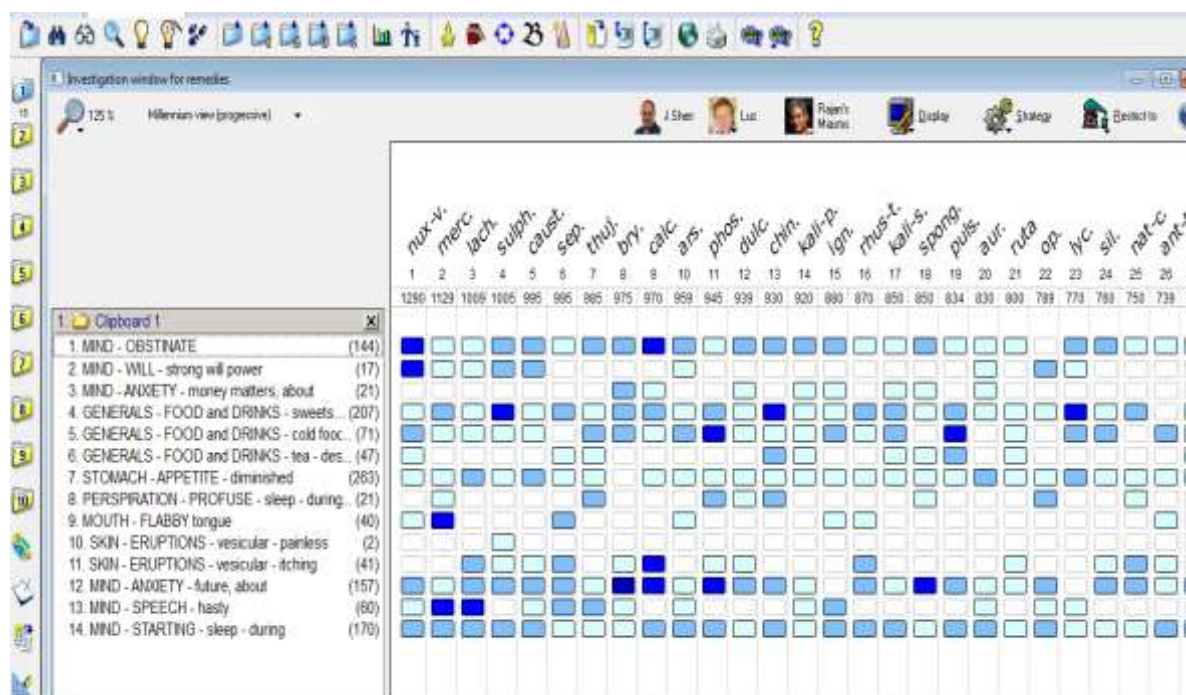
## CLINICAL EXAMINATION

On examination the patient had moist, itchy skin. The blood pressure was 130/90 mm of Hg and the pulse rate was 86 beats per minute. The rest of the general physical examination was found to be normal. The patient was conscious and oriented with normal reflexes, soft and non-tender abdomen and with audible S1 and S2.

## REPERTORISATION

The totality of symptoms of this case includes, headstrong; anxiety about money loss, future ; hurried talking, decreased appetite; sweet, tea and cold food desire; starting in sleep, becomes anxious at night wake up with sweating all over body; affected by both extremes of temperature; flabby large tongue with imprints of teeth; vesicular eruption with itching. After analysis and evaluation of symptoms, this case is worked by synthesis repertory of schroyens using RADAR software, giving priority to mental over physical generals and then to particulars symptoms. merc sol was selected as prescribing remedy as it covers both mental and physical plane of the patient confirmed by different homoeopathic materia medica.

**FIGURE 1: Repertorisation chart**



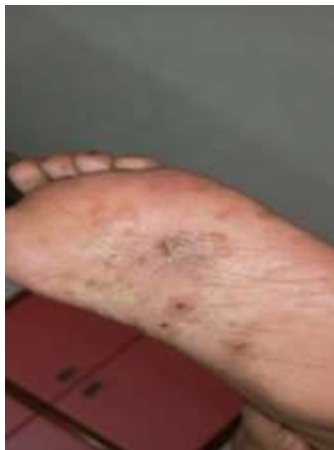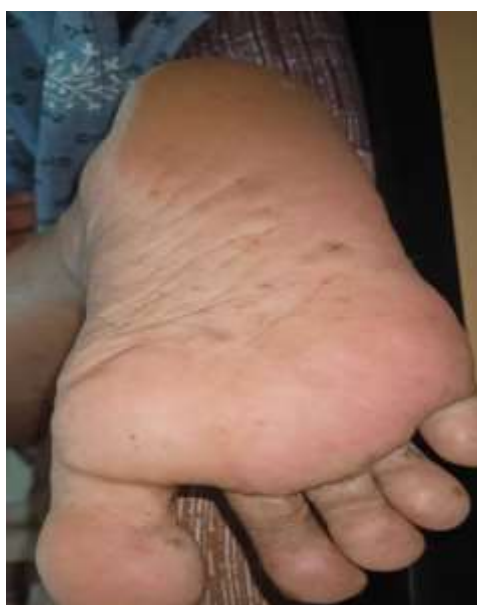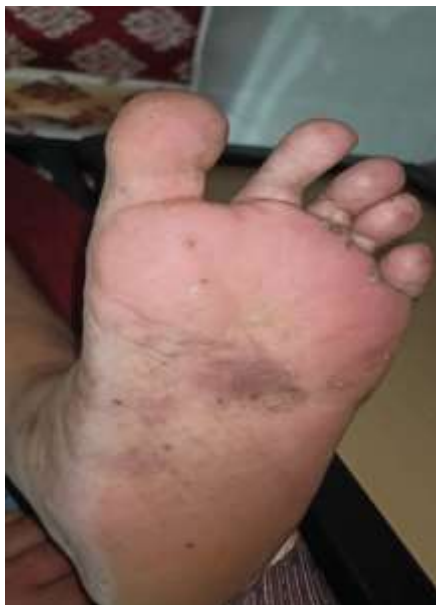## THERAPEUTIC INTERVENTION

After individualisation, single homoeopathic medicine merc sol was selected and prescribed in 30C potency 5 pill single dose on empty stomach on 17 May 2024. The patient was advised diabetic diet to keep control over blood sugar levels. The case is followed up till 14 July 2024. The timeline including the follow up details of the patient are given in (table 1).

**Table 1: Timeline including follow up of the case**

Date	Diet	Follow up	Prescription
17/5/2024	followed	Vesicular eruption over both soles with itching and one suppurating vesicle  Disturbed sleep  Anxiety about money loss	Merc sol 30C stat  Placebo for 15 days
6/6/2024	followed	Itching reduced, eruption reduced 90%  Sound sleep, no anxiety attack  Stress reduced 50%	Placebo for 15 days

		Blood sugar levels were normal	
24/6/2024	followed	Appearance of vesicles in palms and fingers of hand Very tiny itching	Merc sol 30C stat Placebo for 15days
14/7/2024	Followed	Disappearance of all lesion ,no any fresh complaints	Placebo for 15 days medicine stopped.

**FIGURE 2: BEFORE TREATMENT****FIGURE 3: BEFORE TREATMENT****FIGURE 4: AFTER TREATMENT****FIGURE 5: AFTER TREATMENT**

## DISCUSSION

As explained by many studies, homoeopathic interventions prove to be effective in skin diseases. This is due to fact that external manifestation of disease, according to homoeopathy, occur due to some underlying internal derangement and hence they should be treated internally and not locally. In this case, the patient presented with vesicular eruption on both soles. There was itching and suppurating vesicles with fever. The patient thermal reaction was ambithermal. Her appetite was decreased with desire for cold food. Her bowel habits were normal. She had same eruption over hands in past with k/c/o DM and HTN. She seemed very stressed about money loss. anxious about future. Due to this anxiety she gets perspiration with anxiety at night. This case was repertorised using synthesis repertory. After analysis of the result, merc sol was selected and given in 30 CH potency. There was marked improvement in her condition after 2<sup>nd</sup> visit. The eruption gradually became diminished. There was relief in itching. Not only her physical symptoms but her anxiety was also controlled. she was getting better sleep. She was kept on placebo. After few days she got eruption on hand and fingers with slight itching, so dose was repeated. The patient is improved considerably after second dose. The result here in this case was promising however more clinical trials are needed to be done to establish the efficacy of homoeopathic intervention.

---

## CONCLUSION

From this study, it has been observed that homoeopathic medicines are effective in cases of eczema when given on the basis of totality of symptoms as per principles of individualisation. The results are found to be statistically significant. Still there is a need for further studies to provide stronger evidence for proving the efficacy of classical homoeopathy in cases of eczema.

## DECLARATION OF PATIENT CONSENT

The patient was informed about the publication of her data in journal and written consent was taken from the patient

---

## References

1. National eczema association. [Online].; 2017.
2. Neena V ANRA. prevalence of eczema among older persons :A population-based cross-sectional study. Indian J Dermatol Venereol Leprol. 2023;; 89.
3. Hay RJ JNH. The global burden of skin disease in 2010 :an analysis of the prevalence and impact of skin conditions. J invest dermatol. 2014;; 1527-1534.
4. Laughter MR MMS. The global burden of atopic dermatitis :lessons from the global burden of disease study 1990-2017. Br J Dermatol. 2021;; 304-309.
5. RADAR Computer Program
6. W B. New Manual of Homoeopathic Materia medica and repertory : B Jain publishers PVT Ltd ; 2012.