



A Case Report of Nephrolithiasis Treated with Homoeopathy

*Dr. Jagdish Thebar*¹, *Dr. Preeti Srivastav*²

¹Head of Department, Department of Practice of medicine, Swasthya Kalyan Homoeopathic Medical College & Research Centre, Sitapura, Jaipur, Rajasthan, India

²M.D. (PGR), Department of Practice of Medicine, Swasthya Kalyan Homoeopathic Medical College & Research Centre, Sitapura, Jaipur, Rajasthan, India

Email: thebarjagdish@gmail.com

ABSTRACT:

Kidney stones are solid masses comprised of crystals known as Nephrolithiasis^[1] It is an increasing urological disorder of human health, affecting about 12% of the world population. It has been associated with an increased risk of end-stage renal failure.

Case summary- A 25 years old lady was coming in our OPD suffering with pain in lumbo-sacral region since 7-8 days. Specially Right side. The patient was treated with homoeopathic medicines -Berberis vulgaris Q. Follow-up imaging at 2 months showed complete resolution of the nephrolithiasis. This case report highlights the importance of homoeopathic mother tincture prescription as a promising complementary or alternative therapy.

Keywords: Homoeopathy, Case Study, Nephrolithiasis, kidney stone.

Introduction:

The term Nephrolithiasis denotes the development of calculi or stones in the kidneys or urinary tract which may be single, numerous or complex. Stones can develop in the bladder, kidney or pelvis. It is made up primarily of organic material around which the urine salts are dispersed.^[2] Kidney stone are becoming most common throughout India but are especially prevalent in Gujarat, Rajasthan, Punjab and Madhya Pradesh. A urinary tract stone affects about 2% of the community on average, while the actual incidence and prevalence have not been determined. ^[3]

Urinary lithiasis patients rarely feel comfortable in any position. Fever is not present unless a urinary infection also coexists with the calculus but they constantly move about in an effort to “shake off” whatever is making them uncomfortable. Pain and agitation may induce an increase in heart rate and blood pressure. ^[4]

- A moderate amount of deep discomfort can be felt while palpating the calculus and the loin area of the abdomen.
- Pain in the back side and area below the ribs. Fluctuations in pain severity with intervals of discomfort lasting 20 to 60 minutes are typical. This pain often exclusively affects the side of the nephrolithiasis.
- Lower abdominal and groin pain that radiates from the side and back.
- Bloody, murky or foul-smelling urine.
- Pain, swelling and discomfort after urinating.
- Nausea and vomiting.
- A persistent urge to urinate.
- If an infection is present, fever and chills.

Previous research: This study was the efficacy of homoeopathic medicine in the management of renal calculi, to study the Homoeopathic approach to avoid surgery and recurrence of stone formation. From this study it is evident that majority of cases of Renal calculi can be effectively relieved by

Past- history: Renal calculi Right side 2.6 mm calculi (2019) Taken Ayurvedic Treatment and allopathic medicines.

Mental-generals:

- Anger ++.she screams angrily and throw things.
- Introvert
- Desire open air
- Consolation aggravation
- Fear of darkness

Physical Generals:

- Appetite – Diminished, (2 chapattis in day time & 1 chapatti in night or patient sometimes skip the meal) prefer warm food.
- Thirst–Decreased 2-3 glass of water / Day, SQLI .
- Desire – Salty++, sweet
- Aversion – Green chilly
- Stool–Regular, unsatisfactory 2-3 times daily, semi solid consistency.
- Urine–D5-6; N-3-4. Dark yellow colour urine, no odour, painful urination, burning after urination & frequent urination.
- Perspiration–Profuse specially on face. No staining & No odour.
- Sleep/ dreams – 6-7 hrs unrefreshing sleep dullness sensation
- Addiction– Smoking since 5 years; 2-3 cigattes/Day & occasionally drink
- Thermal reaction – Chilly

Menstrual history - Menarche – 13 years of age LMP- 10/06/2022 6/24-25 days, bright red .

- White discharge before and after menses. Acrid, pale colour & thick discharge.

Sexual History : Active , Burning during coitus

General examination: Height – 160 cm

Weight – 65 kg

BMI-25.4Kg /m²

Nails: Healthy

Blood pressure: 120/80 mm of Hg

Respiratory rate: 17/min

Pulse: 80/min

Temperature: 98.6 °F

- **INVESTIGATION** -USG of whole Abdomen on 16.07.2022 reported. Finding USG Report 7.5 mm calculi in middle calyx of right Kidney.

Analysis of Case: (According to kent)

Mental Generals	Physical Generals	Particulars
<ul style="list-style-type: none"> • Anger ++.she screams angrily and throw things. • Introvert • Desire open air • Consolation aggravation • Fear of darkness 	<ul style="list-style-type: none"> • Appetite - Diminished, prefer warm food. • Thirst–Decreased • Desire – Salty++, sweet • Aversion -Green Chilly • Addiction– Smoking since 5 years; 2-3 cigattes/Day & occasionally drink • Thermal reaction – Chilly 	<ul style="list-style-type: none"> • Pain in lumbo-sacral region. • Burning after urination • Painful & Frequent urination urination • Nausea sensation.

Evaluation of Symptoms:

- Angry++
- Consolation aggravation
- Appetite - Diminished
- Thirst – Decreased,
- Desire – Sweets & salty ++
- White discharge before and after menses. Pale color
- Craving for tobacco
- Thermal - Chilly
- Pain in Lumbosacral region specially Right side
- Burning after urination
- Painful & Frequent urination
- Nausea

Prescription: 16/07/22**Rx**

Berberis Vulgaris Q/TDS/10-10-10 Drops in ¼ cup of Lukewarm Water

Rubrum 30 TDS X 14 Days

General Management

- Drink plenty of fluid: 3-4 liter/day.
- Spinach, berries, Tomatoes, nuts, beets, tea should be limited.
- Avoid extra calcium & sodium supplements.
- Avoid high doses of vitamin C supplements.
- Avoid smoking.

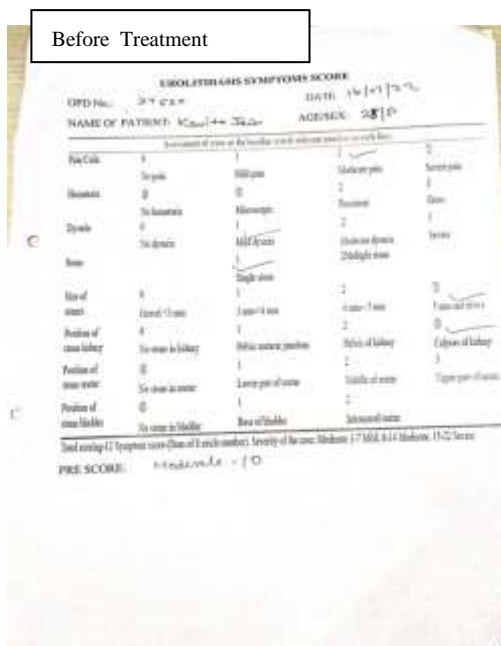
Follow up:

DATE	SYMPTOMS	PRESCRIPTION
30/07/2022	slight relief in burning in urination No relief in pain but she feels better now Relief in painful urination LMP- 18/07/2022	Rx Rubrum 30/ TDS x 15 Days
13/08/2022	Slight Relief in Pain Relief in burning and painful urination slight relief in white discharge	Rx Berberis Vulgaris Q/TDS/ 10-10-10 Drops in ¼ cup of Lukewarm water Rubrum 30/ TDS x 15 Days
27/08/2022	Relief in pain Relief in burning & painful urination LMP- 13/08/2022 Relief in white discharge	Rx Rubrum 30/ TDS x 15 Days
10/09/2022	Pain in groin region & painful urination since 3 days Relief frequent urination Relief in burning LMP- 09/09/2022 Advice- USG of KUB	Rx Berberis Vulgaris Q /TDS/ 10-10-10 Drops in ¼ cup of Lukewarm water Phytum 30 TDS x 15 Days
23/09/2022	Relief in pain and painful urination No New symptoms appear Stone expelled out	Rx Placebo 30/TDS x 15 Days
06/10/2022	Relief in all complaints No new symptoms appear	Rx Placebo 30/TDS x 15 Days

On 20/10/22 patient again gave her follow- ups, there is no recurrency of symptoms. Patient was quite happy and healthy now adays.

USS Score Before and After Treatment :

Before Treatment



The image shows a handwritten 'UROLETHIASIS SYMPTOMS SCORE' form for a patient. The patient's name is 'K. S. S. S.' and the date is '10/10/22'. The form includes a table with 5 columns and 10 rows of symptoms, each with a score from 0 to 4. The 'POST SCORE' is calculated as 10.

After Treatment




The image shows a handwritten 'UROLETHIASIS SYMPTOMS SCORE' form for the same patient. The patient's name is 'K. S. S. S.' and the date is '06/10/22'. The form includes a table with 5 columns and 10 rows of symptoms, each with a score from 0 to 4. The 'POST SCORE' is calculated as 0.

Report

Report Before



Report After



Discussion:

In the given case of Nephrolithiasis Homoeopathic Mother Tincture *Berberis vulgaris* Pain in thigh and loins on urinating, frequent urination is most valuable symptoms.^[10] *Berberis vulgaris* is a best medicine for both sided of renal stone. **Similarly, in previous researches**

Previous research :- To study the efficacy of homoeopathic medicine in the management of Renal Calculi and to study the Homoeopathic approach to avoid Surgery and recurrence of Stone formation. this study showed that the Most commonly age group 30-45 with 47%. About 5 remedies were efficacious in the treatment of renal calculi. Out of 30 cases 5 cases recovered, 23 improved and 2 cases did not improved. From this study it is evident that majority of cases of Renal calculi can be effectively relieved by homoeopathic constitutional treatment. Homoeopathy by addressing all aspect of the individual and their complete set of symptoms offers better treatment for patients suffering from Renal calculi. Homoeopathic remedies to begin with reduce the frequency of acute exacerbations, reduce the intensity of symptoms and reduce the relapse and chances of recurrence and their by remove stones. They reduce dependence over other and also surgery.^[5]

Conclusion:

From this study it can be concluded that Homoeopathic Mother Tinctures are helpful in reducing Urolithiasis Symptom Score Scale, symptoms decreased and improved quality of life in cases of Nephrolithiasis. Homoeopathic management has shown tremendous result in the cases of Nephrolithiasis.

References:

1. Kansal Kamal, Kaushal Rakesh, Textbook of Practice of Medicine with homoeopathic Therapeutics. Third Revised and Enlarged Edition. NEW DELHI; B. Jain Publishers (P) Ltd. (2017)
2. Chhiber N., Sharma M., Kaur T., Singla S. Mineralization in health and mechanism of kidney stone formation. International Journal of Pharmaceutical Science Invention. 2014; 3:25-31.
3. Chug S.N., Text book of Medicine For MBBS. First Edition.VOL. 2. DELHI ARYA PUBLICATIONS. (2007)
4. Walsh, Patric C. Retick Alan B, Vaughon, E Darracott Tr, Campbell's urology. Vol. III, IV edition. W.B. sounders co: 1998 P.No. 2662 – 2665, 2699 2706 – 2707.
5. Singh Rathore R, Aggarwal A, Reddy P, Sharma C. Pranab Kumar Chakraborty: a study to ascertain the effect of berberis vulgaris, hydrangea, cantharis, lycopodium clavatum and staphysagria in renal calculi. Tania University Journal of Homoeopathy and Medical Science Original Article [Volume3]Issue4 |Oct.-Dec.2020]

6. Christopher R.W. Edward and Lan A.D. Bonchief (ed). Davidson principles and of medicine. 16th edition ELBS with Churchill Livingston Publications:1993 P.No. 569-597.
7. Lareau SM, Beigi RH. Pelvic inflammatory disease and tubo-ovarian abscess. *Infect Dis Clin North Am* 2008;22:693.
8. Rodkey GV, Welch CE. Changing patterns in the surgical treatment of diverticular disease. *Ann Surg* 1984; 200:466.
9. Türk C, Neisius A, Petrik A, etal. European Association of Urology. Urolithiasis.2020.
10. Boericke W. New Manual of Homoeopathic Materia Medica and Repertory. Boericke W, Sivaraman P, editors. New Delhi, India: B Jain; 2002.