



## Homoeopathy for Urticaria: A Case Report

<sup>1</sup>Dr. Nitiksha Sharma, <sup>2</sup>Dr. Pavitra Gaur, <sup>3</sup>Dr. Kanak Chaudhary

<sup>1</sup>M.D. (PGR) Materia Medica, Swasthya Kalyan Homoeopathic Medical College and Research Centre, Jaipur (Raj.), India.

<sup>2</sup>M.D. (PGR) Materia Medica, Swasthya Kalyan Homoeopathic Medical College and Research Centre, Jaipur (Raj.), India.

<sup>3</sup>M.D. (PGR) Organon of medicine, Swasthya Kalyan Homoeopathic Medical College and Research Centre, Jaipur (Raj.), India.

### ABSTRACT:

Urticaria is the most frequent dermatological disorder. A kind of skin condition characterized by elevated, itchy, red bumps. Urticaria is a complex medical condition that results in significant illness and a noticeable decrease in quality of life due to its intricate pathophysiology. Commonly, urticaria manifests clinically as wheals, angioedema, or both. Angioedema, a localized, self-limiting oedema of the subcutaneous and submucosal tissue.

**Case summary:** A 36 years old lady was coming in our OPD suffering with reddish bumpy eruptions persist with itching around lips area for 1 year. A complete analysis of the case helps to choose China officinalis on the basis of individualization. This case report explores the role of homoeopathy in treating urticaria, providing insight into its use in the homoeopathic management of skin conditions. China officinalis has been used effectively in aiding a person's full recovery from skin ailment like urticaria.

**Keywords:** Urticaria, Homoeopathy, case- report.

### Introduction:

Urticaria, commonly known as Hives, is a skin condition characterized by red, raised, and itchy bumps on the skin, caused by regional swelling. Urticaria can be a chronic skin condition that affects many individuals, causing discomfort and inconvenience throughout their lives. It's worth noting that, statistically speaking, women are more likely to be affected by this ailment than men <sup>[1]</sup>. Urticaria, or hives, can cause uncomfortable skin swelling due to the increased permeability of capillaries. Seeking prompt medical attention can help alleviate symptoms and prevent potential complications. <sup>[2]</sup>More than half of chronic urticaria cases is caused by autoantibodies, which is a type of autoimmune mechanism. <sup>[3]</sup>

### Previous research:

A significant percentage of patients referred to dermatological clinics have urticaria. An evidence-based case study of Urticaria demonstrates that, following a thorough patient assessment, carefully chosen constitutional medication treats urticaria. This case report will increase understanding and encourage aspiring homeopaths to investigate the potential benefits of homeopathy for comparable dermatological conditions <sup>[4]</sup>

### Differential diagnosis:

- a) Allergic contact dermatitis
- b) Dermatitis herpetiformis.
- c) Systemic lupus erythematosus.
- d) Atopic dermatitis (eczema)
- e) Erythema multiforme
- f) Pityriasis rosea.
- g) Maculopapular drug eruptions.

**Diagnosis: Atopic Dermatitis (Eczema)****Case- report:**

Date of case Definition: 15/03/22

**Consent form:**

**Swasthya Kalyan Homoeopathic Medical College & Research Centre**  
10, Sitapura Institutional Area, Sitapura, Tonk Road, Jaipur

Consent letter

I Smita, Shashika Age / Gender 36yr / F have come to Swasthya Kalyan Homoeopathic Medical College and Research Center 10-A Institutional Area - Sitapura, Tonk Road, Jaipur, for the treatment of urticaria. Here I am briefed about the ongoing research. I have complete freedom to ask any kind of question regarding related research and treatment. I understand my permission to allow other regulatory authorities acting on behalf of the sponsor of clinical trials to view my health records in the case of both the current study and future research that may be conducted in connection with it. However, I understand that my identity will not be disclosed in any information released or published to third parties. I want to be a part of it of my own free will and I can do my best at any time without giving any reason. I am free to opt out of this study without affecting my medical or legal entitlements.

Signature: Smita  
Relation with patient: -  
Date: 15/03/22  
Location: Swasthya Kalyan Homoeopathic medical college & Research center

**Presenting- Complaints:**

1) A 36 years old lady was coming in our OPD suffering with reddish bumpy eruptions persist with itching around lips area for 1 year.

Time of itching- Not specific.

Modalities: Itching was chiefly aggravated in summers.

Ameliorated from open air and from applying ointments (Allopathic).

No concomitants were present.

2) Patient was suffering from bloating and heaviness in the whole abdomen for 6 months.

**History of presenting complaint:** Patient was healthy 1 year back, then she starts suddenly feels persecuted against everyone in her family except her husband and children, then after timepasses, she starts feeling eruptions around lips area with intense itching.

**Past- history:** Nothing specific.

**Mental- generals:** She starts feel persecuted by others (Delusion).

Nervous person (During observation)

Hopeful person for every situation and work done by herself.

She always lived in an imaginary and fantasizing world; she thinks that everyone in her family is persecuted herself. She builds a story in any situation.

**Physical- generals:****Appetite:** Normal, 2-3 meals/ day. (chapati/ time)**Thirst:** less than 1 litres/ day. (Thirstless)**Desire:** Sweets.**Aversion:** not specific.**Stools:** satisfactory stools (D<sup>1</sup>) with bloating abdomen.**Urine:** normal clear. (D<sup>0-5</sup>, N<sup>0</sup>)**Perspiration:** normally on forehead.**Addiction:**not specific**Thermal:**chilly patient**Bathing- Habits:**Regular in habit.**Sleep and dreams:**sound sleep, refreshing (5-6 hrs/ day)**Physical- Examination:****Respiratory:** 16/min**Pulse:** 72/ min**Temperature:** 98.6°F**Blood pressure:** 120/80 mm of hg**Height:** 5'2 ft.**Weight:** 57 kg**Tongue:** moist and clear**Lymph nodes:** normal.**Analysis of Case: (According to kent)**

Mental- generals	Physical- generals	Particulars
She starts feel persecuted by others (Delusion).	Thirstless.	Reddish bumpy eruptions with itching around lips area.
Nervous person (During observation)	Desire for sweets.	Modalities: Itching was chiefly aggravated in summers.
Hopeful person in every situation and work done by herself.	Perspiration on forehead.	Ameliorated from open air and from applying ointments (Allopathic).
She always lived in an imaginary and fantasizing world; she thinks that everyone in her family is persecuted herself. She builds a story in any situation.	Thermal- Chilly patient.	Patient was suffering from bloating and heaviness in the whole abdomen.

**Evaluation of symptoms:**

She starts feel persecuted by others (Delusion).

Nervous person (During observation)

Hopeful person in every situation and work done by herself.

She always lived in an imaginary and fantasizing world; she thinks that everyone in her family is persecuted herself. She builds a story in any situation.

Thirstless.

Desire for sweets.

Perspiration on forehead.

Thermal- Chilly patient.

Reddish bumpy eruptions with itching around lips area for 1 year.

Modalities: Itching was chiefly aggravated in summers.

Ameliorated from open air and from applying ointments (Allopathic).

Patient was suffering from bloating and heaviness in the whole abdomen.

#### **Totality of Case:**

She starts feel persecuted by others (Delusion).

Nervous person (During observation)

Hopeful person in every situation and work done by herself.

She always lived in an imaginary and fantasizing world; she thinks that everyone in her family is persecuted herself. She builds a story in any situation.

Thirstless.

Desire for sweets.

Perspiration on forehead.

Thermal- Chilly patient.

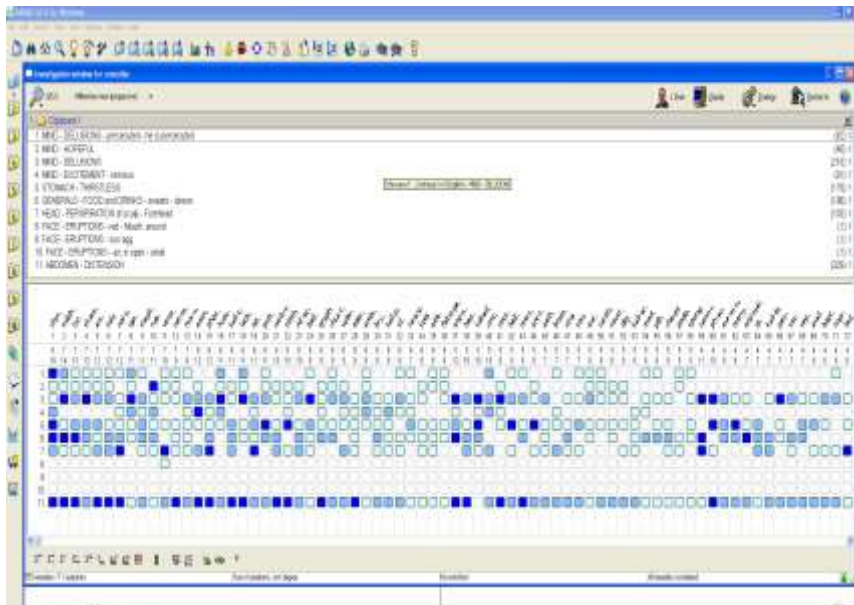
Reddish bumpy eruptions with itching around lips area for 1 year.

Modalities: Itching was chiefly aggravated in summers.

Ameliorated from open air and from applying ointments (Allopathic).

Patient was suffering from bloating and heaviness in the whole abdomen.

#### **Repertorial- sheet:**



#### **Prescription: (15/03/22)**

China 30/ 1 Dose/ H.S. (At Night)

Rubrum 200/ Thrice Daily.

For 15 days

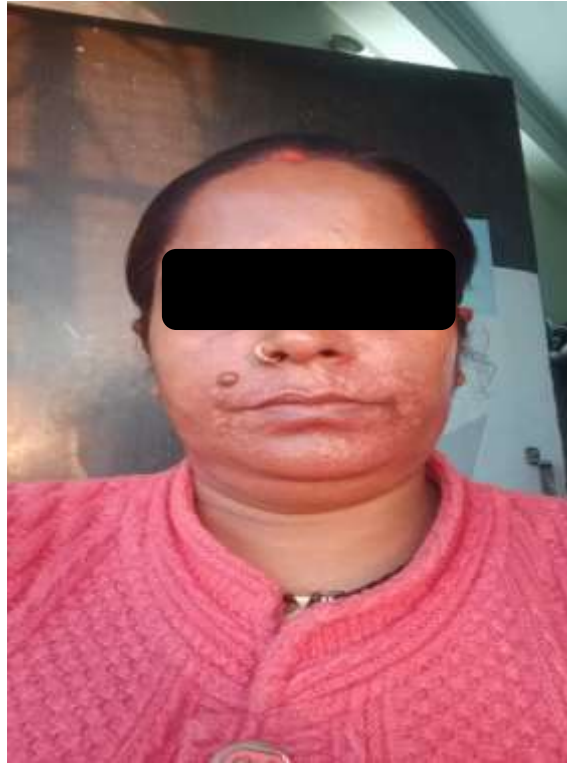**Follow- ups:**

Date	Changes in Symptoms	Prescription
1/04/23	Slight relieve in reddish bumpy eruptions No relief in itching. Slight relieve in abdomen distension and heaviness too. Slight relieve in delusions (According to patient).	Rubrum 200/ Thrice daily For 15 days
16/04/23	Slight relieve in eruptions with now there is slight relieve in itching. Relieve in thinking that everyone is persecuted her (According to patient). Relieve in bloated abdomen and heaviness too. No concomitants.	Rubrum 200/ Thrice daily For 1 month
18/05/ 23	Relieve in Eruptions completely. No itching no reddish bumpy eruptions. Relieve in her thinking too. Relieve in abdomen distension and in heaviness. No Concomitants.	Rubrum 200/ Thrice daily. For 2 months
18/07/23	Relieve in all symptoms No concomitants.	

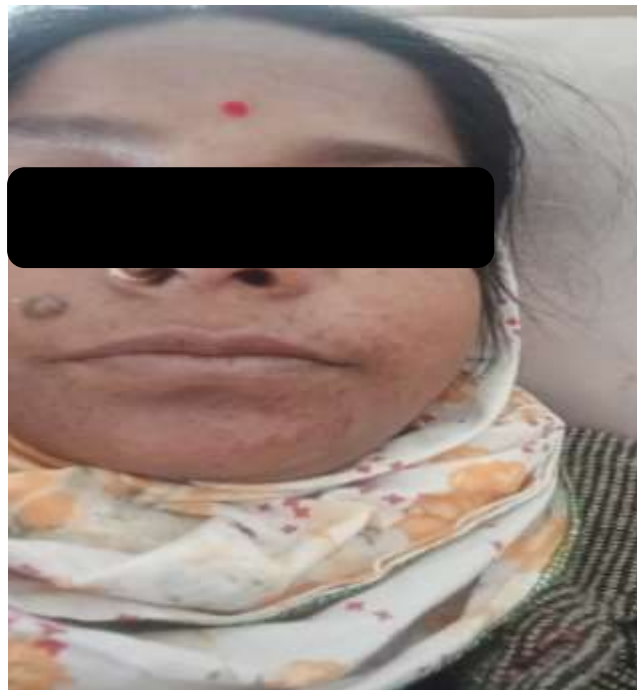On 20/09/23 patient again gave her follow- ups, there is no recurrency of symptoms. Patient was quite happy and healthy nowadays.

Images:

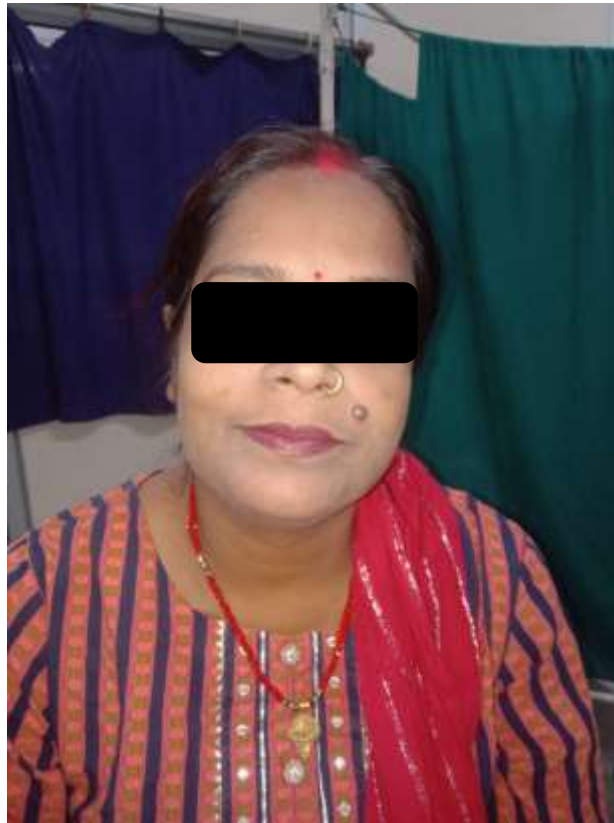15/03/22



16/04/22



18/05/23



---

**Discussion:**

In the given case of urticaria, homeopathic medicine (China officinalis) helps to treat the individual and provide complete relieve from the symptoms.

**Similarly, in previous researches:**

**Case report Summary:** A male child came with the complaint of Itching of the whole body that indicates a comprehensive assessment of the patient, followed by the prescription of the appropriate constitutional medicine. <sup>[4]</sup>

**Case- Report summary:** A 23-year-old male having complaint of urticaria all over the body past one year in which sulphur 200 was given on the basis of individualization which helps them to recover from it completely. Individualize homeopathic remedy indicate an approach to cure the individual from any kind of ailment. <sup>[5]</sup>

Based on individualization homeopathic medicine was selected in the case of urticaria, which helps in getting rid of the symptoms. The homeopathic approach treats the patient as a whole, taking both mind and body into consideration, using a holistic method. After taking the medication (China officinalis), both the physical and emotional symptoms were noticeably reduced, including rash, burning, and itching. Following treatment, all symptoms disappeared completely.

---

**Conclusion:**

This case study explores the clinical implications of integrating China officinalis medicine into constitutional treatment. The findings provide valuable information to the existing body of knowledge, endorsing the use of China Officinalis. The positive results obtained in this particular case of urticaria, support the need for further research.

---

**References:**

- 1) Chakraborty DPK, Aggarwal DA, Singh DV, Kuntal DRS. Constitutional treatment of Chronic Urticaria in Homeopathy: A case report. Int J Homoeopathic Sci [Internet]. 2022;6(4):359–62. Available from: <http://dx.doi.org/10.33545/26164485.2022.v6.i4f.681>.
- 2) Sharma A, Kushwaha NS. Urticaria and its homeopathic approach [Internet]. Ijert.org. [cited 2023 Dec 12]. Available from: <https://ijert.org/papers/IJERT2109306.pdf>.

- 3) Goh CL, Tan KT. Chronic autoimmune urticaria: where we stand? *Indian J Dermatol*. 2009 Jul;54(3):269-74. doi: 10.4103/0019-5154.55640. PMID: 20161862; PMCID: PMC2810697.
- 4) Chitre SK. Evidence based homoeopathy: Case report on urticaria [Internet]. Org.in. [cited 2024 Jan 29]. Available from: <https://mhmc.org.in/wp-content/uploads/2022/09/Evidence-Based-Homoeopathy-Case-Report-On-Urticaria.pdf>
- 5) Me A. Efficacy of homeopathic treatment in urticaria-a case report [Internet]. Homeopathy Resource by Homeobook.com. Homeobook; 2021 [cited 2024 Jan 30]. Available from: <https://www.homeobook.com/efficacy-of-homeopathic-treatment-in-urticaria-a-case-report>