



A Randomized trial to see the Effectiveness of Homoeopathic Medicine Sarsaparilla 30 in Case of Renal Stone: A Case Report.

Dr. Nirmala Sharma (M.D. Hom) (1), Dr. Swati Sharma (M.D. Hom) (2)

¹.Assistant professor, Department of Obstetrics and Gynaecology, University College of Homoeopathy, Kekri, Ajmer, Rajasthan, India.

².Assistant Professor, Dept. of Surgery, University College of Homoeopathy, Kekri, Ajmer, Rajasthan, India.

ABSTRACT:

Renal stone is a condition of formation of crystal concretion in kidney. It may be in the Upper, Middle or lower calyx of kidney. It affects almost 12% of Global population. Renal stone is a growing urological and most common renal disease. Renal stone is the most common cause of Hematuria (Blood in urine) and pain in abdomen, Flanks and/or groin. Complication includes renal failure if proper treatment does not take. Recurrent renal calculi can damage the tubular epithelial cells, which can lead to functional loss of renal parenchyma. According to the ultrasonography results used in this case report; the patient had bilateral renal calculi. Homeopathy is the most gentle and rapid way to remove Renal stone. In this case the homoeopathic medicine prescribed after detail case taking, Evaluation of symptoms, in-depth analysis and repertorisation of symptoms.

Keywords: Renal Calculi, Homoeopathy, Sarsaparilla, Haematuria.

Introduction:

Renal stone occur in one in 11 people at some time in their lifetime. Man affected 2 to 1 over women. Development of stone is related to decrease urine volume, dribbling of urine, Hematuria, Pain in renal region. Symptoms that frequently associated with renal calculi are Excretion of Hematuria (blood in the urine) and pain in the belly, flank, or groin. Stone development is correlated with lower urine output or increased excretion of substances that contribute to the formation of stones, including calcium, oxalate, uric acid, cystine, xanthenes, and phosphate. Calculi can also result from high urine acidity or low urinary citrate levels ⁽¹⁾.

Conventional treatment primarily includes surgical intervention like lithotripsy. Different Homoeopathic literature has shown the importance and efficacy of homoeopathic medicine in eliminating the renal calculi ^(2,3) Homeopathy is the most Natural, gentle and effective way to remove renal stone and it also treat the root cause of the disease, so chances of suffering from renal stone in future will be very less or nil. Homeopathy is the natural way of cure and safe way of treatment. Homeopathic medicine decreases the propensity of formation of renal stone. It also helps in breakdown the stone in sand like particles. Then it helps to dilate the ureter and remove the stone without any adverse effect. ⁽⁴⁾

Case Study: The reported case is 18 years old, Male, Hindu, vegetarian, student by profession, Residing in rural area and belonging to a middle socio-economic family, who came to our OPD (1191) of 20/07/2021 with the complaint of

1. Pain in both lumber region which referred to thighs. Pain > by pressure.
2. Burning micturition, severe pain especially at the Conclusion of urination.
3. Pain from kidney region to downward, Renal Colic.
4. Stitching pain and burning with dribbling of urination < End of the micturition. Pain in both lumber regions since 1month. Complaints of intermittent urination since 10 days.
5. White sand in urine sometimes.

Treatment History - He took allopathic treatment for 10 days, but only temporary relief was obtained.

Family History - Father History of Renal stone. Mother and all siblings are healthy.

Patient as whole:-

Appetite- Good, 4 chapati/ meal and 2 Meals/Day.

Thirst- Thirsty, drinks 4 Liters / day.

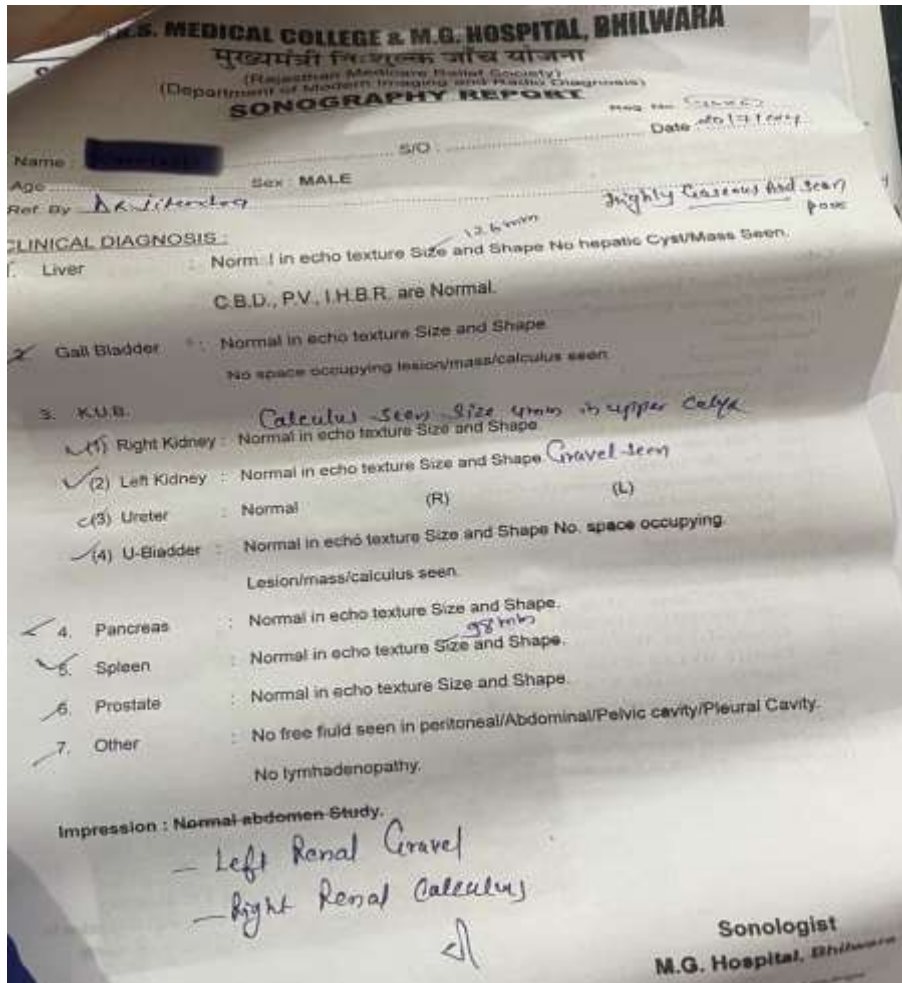
Stool- once a day, satisfactory, hard solid.

Urine- Pale yellow, non-offensive, Sometimes White sand in urine, burning micturition especially at the end of Micturition. Can't pass urine while sitting.

Perspiration- Not specific. Thermal reaction- Chilly. Mentals – Sensitive and despondent. Easily offended, Ill Humored observed during case taking.

General examination: Patient was apparently healthy looking. Anaemia/pallor - Absent, facies- absent, cyanosis- absent, deformity-absent, oedema - absent, skin- dry, cachexia/ emaciation-absent, weight – 48 kg, SpO2- 98%, temperature – Afebrile, height – 166cm, built – ectomorphic, blood pressure- 120/80 mm Hg, respiratory rate - 18/ min, tongue – clean, pulse 78/min.

Local examination: Tenderness in right lumbar region. Provisional diagnosis Renal calculi present in right and left kidney. Right Kidney- 4mm stone in upper Calyx. In Left Kidney- Gravels seen. (Figure 1)



Case Processing:-

Table 1: Evaluation and Miasmatic Analysis of symptoms.

Symptoms	Evaluation	Miasmatic analysis
Despondent	+3	Psora
Sensitive	+3	Psora
Easily offended	+3	Syphilitic
White crystal in urine.	+3	Psora-Sycotic
Burning at the end of micturition.	+2	Psora-syphilitic
Stitching pain after Urination.	+2	Psora- Syphilitic

Case Processing:-

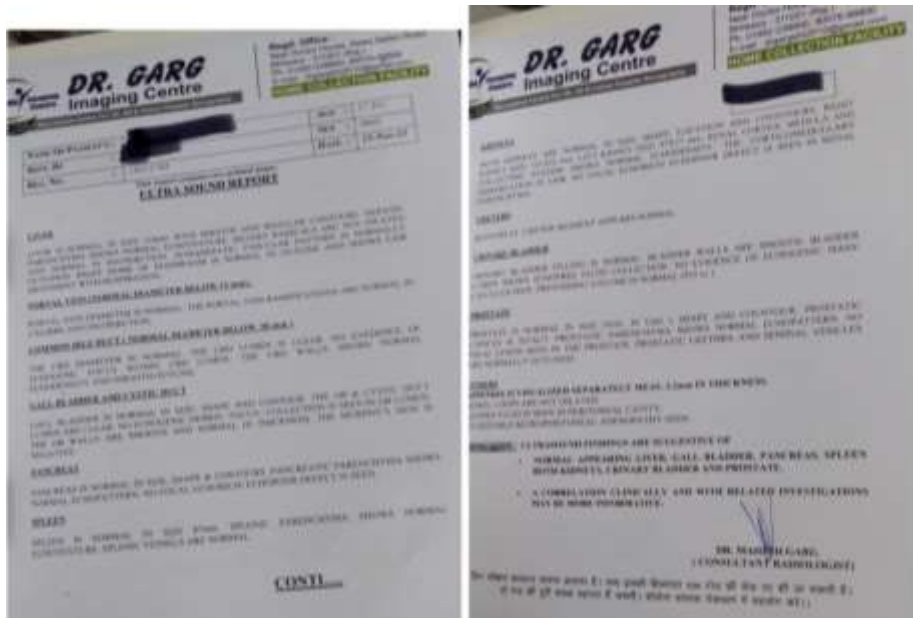
Repertorisation: - In this case General symptoms were marked so this case was repertorised with the help of Synthesis repertory from RADAR 10.0 version. (Figure 2)

Selection of potency and dose:- Sarsaparilla 30 was given TDS.

General Management – Drink 4-5 Liters of water every day. Go for urine when bladder is full. Avoid consuming seedy vegetables and fruits. Avoid milk and milk products.

Table 2:- Follow Ups during treatment.

Date	Change in symptoms	prescription	Justification
20/07/2021	Stitching pain in lumber region refer to thighs. Nausea and vomiting. Dribbling of urination. Burning at the end of micturition. Sometimes white crystal found in urination.	Sarsaparilla 30 TDS x 15 Days	According to symptoms similarities medicine Sarsaparilla prescribed.
04/08/2021	Same symptom present but severity decreased.	Sarsaparilla 30 TDS x 15 Days	Symptoms relieved so repeated the medicine.
19/08/2021	No pain, No nausea. Burning at the end of micturition relieved.	Sarsaparilla 30 TDS x 15 Days	Symptoms relieved so repeated the medicine.
14/08/2021	No white crystals found in urine. All symptoms relieved.	Sarsaparilla 30 TDS x 30 Days	Symptoms relieved so repeated the medicine.
15/09/2021	All the Symptoms relieved. Sometimes dribbling of urination.	Sarsaparilla 30 TDS x 30 Days	Symptoms relieved so repeated the medicine.
16/10/2021	Almost all symptoms Subside. General wellbeing.	Rubrum30 TDS x 15 Days	No Symptoms so Rubrum 30 was prescribed.
30/10/2021	Patient felt something passed while urination. Patient advised to get sonography.	Phytum 30 TDS x 15 Days	No Symptoms so Phytum 30 was prescribed.
15/11/2021	No symptoms at all. No Prescription No calculi seen in sonography.	Placebo 30 TDS x 15 Days	No recurrence of symptoms so Placebo was given.



Discussion and conclusion-

In the surgical cases like Nephrolithiasis Homeopathy offers a secure and efficient option. We also found that a similimum medicine provided individually and based on totality can work in this situation. Here Sarsaparilla being the Similimum cured the patient.

Some symptoms considering Sarsaparilla as given in Literature are - Renal colic, Urinary symptoms well marked, urine scanty, slimy, Flaky, sandy, Bloody, Gravel. Severe pain at conclusion at Conclusion of urination. Child screams before and while urination. Pain in right kidney downwards. (9).

This case shows that homeopathic treatment act as a possible complementary or alternative therapy. Further analysis of the constitutional approach requires investigation into related cases.

Acknowledgement: - We heartily thankful to University College of Homoeopathy, Kekri.

Conflict of Interest: - The authors declare that there is no conflict of interest regarding the study or this article.

Abbreviations Outpatient department (O.P.D.), thrice a day (T.D.S.) Adverse Drug Reaction Not reported

Limitations:

Nephrolithiasis cases complicated with other renal disease requiring urgency should not be treated with Homoeopathy. Large Staghorn calculi obstructing urinary passage may require emergency treatment. This is a single case report. In future case series can be recorded on effectiveness of individualized homoeopathic medicine in renal stones.

Funding - Nil

References :

1. Leslie SW, Hussain Sajjad, Murphy PB. Renal Calculi [Internet]. Nih.gov. Stat Pearls Publishing; 2019. [cited 2023 Feb 12] Available from: <https://www.ncbi.nlm.nih.gov/books/NBK442014/>
2. Sumithran PP. A case of multiple urinary calculi. *Indian Journal of Research in Homoeopathy*. 2016;10(2):142.
3. Mukharjee HK, Das D, Haque S, Chatterjee S, Nandi J, Guha B, et al. Non-surgical expulsion of renal stones (calculi) with homoeopathic remedies: A dependable alternative option. *Int J Curr Adv Res*. 2018;7:9908- 18.
4. Best Homeopathic Medicines For Kidney Stones! - By Dr. Lalit Kasana [Internet]. Lybrate [cited 2023 Feb 14] Available from: <https://www.lybrate.com/topic/best-homeopathic-medicines-for-kidneystones/242ccc65517524fff06789aeed60897d>
5. Patel R. Chronic miasms in Homoeopathy & their cure with classification of their rubrics/ symptoms in Dr. Kent's repertory (Repertory of miasms). New Delhi: B. Jain; 1996
6. Kent JT. Lectures on homoeopathic materia medica: together with Kent's "new remedies" incorporated & arranged in one alphabetical order. New Delhi: B. Jain; 2015.
7. Boericke W, Boericke OE. Pocket manual of homoeopathic materia medica: comprising the characteristic and guiding symptoms of all remedies (clinical and pathogenetic). New Delhi: Indian Books & Periodicals Publishers; 2004.
8. Britton R, Hobson R, Penman ID, Ralston S, Strachan MWJ. Davidson's Principles and Practice of Medicine. 23rd ed. Edinburgh: Elsevier; 2018.
9. Hering C. The Guiding Symptoms of Our Materia Medica. B. Jain Publishers; 2005