



A Review: Mucormycosis Covid-19

Shirsat Komal Changdev¹, Dr. Gavade. S.P.²

¹Student: (B.pharm), ²Assistant Professor; Late Narayandas Bhavandas Chhabada Institute of pharmacy, Raigaon, Satara.

Author for Correspondence: Department of Pharmacology, Late Narayandas Bhavandas Chhabada Institute of Pharmacy, Raigaon, Satara, Shivaji University, Kolhapur, Maharashtra, India. Gmail: Komalshirsat007@gmail.com, Shivajigavade86@gmail.com

ABSTRACT:

Now days many cases of coronavirus disease has been reported worldwide due to which the frequency of bacterial and fungal co-infection has been rising continuously While mucormycosis cases are also recognized in association with COVID-19. The fungal co-infection developed in COVID-19 patients known as mucormycosis a black fungal infection which mainly leads to loss of sight and hearing capacity which eventually leads to death of that patient. The main reason of this arising disease is the steroid treatment given in COVID-19 cases. This report aims to address the importance of short term follow up in COVID-19 patients who have received corticosteroids which results in life threatening mucormycosis infection. The early detection, aggressive treatment is essential for management of invasive fungal infection. This report mainly focus on the mucormycosis , black fungal infection caused during post COVID complications. It usually affects those which have health problems or who are taking drugs that limits body ability to compete with germs and illness. The main cause of this infection is use of steroids in management of COVID infection as well as the fact that many COVID patients had diabetes as co-morbidity.

Keywords: Mucormycosis; Covid-19;causes;Treatment; infection; prevention; control

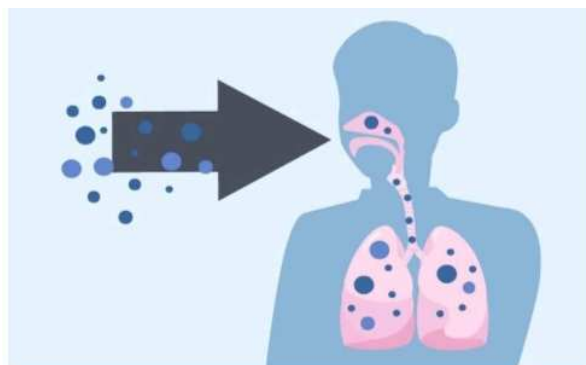
INTRODUCTION:

COVID-19 caused by severe acute respiratory syndrome corona virus- 2(SARS -COV -2) has been associated with opportunistic bacterial and fungal infection. The Aspergillosis and Candida both are responsible for co-infection in people with COVID-19. Now days many cases of mucormycosis are reported worldwide in COVID-19 patients.

The main reason of germinating Mucorales spores in people with COVID-19 is the conditions such as low oxygen (hypoxia) ,high glucose (diabetes new onset hyperglycemia ,steroid induced hyperglycemia), acidic medium (metabolic acidosis ,diabetic ketoacidosis),high iron levels and decreased phagocytic activity of white blood cells (WBC) due to immunosuppression (SARS COV- 2 mediated , steroid mediated or background comorbidies) such conditions or due to other risk factors such as prolonged hospitalization with or without mechanical ventilators are responsible for increasing cases of mucormycosis in COVID-19 patients. In 1885 Phycomycosis and Zygomycosis was described by Paltauf and later it coined as mucormycosis by Baker in 1957. Mucormycosis is fatal fungal infection which affects patients with altered immunity. Mucormycosis caused by mold fungi of genus *Rhizopusmucor*, *rhizomucor*, *cunninghamella* and *absidia* of order Mucorales class -zygomycetes. Nearly 60%of mucormycosis caused by *RhizopusOryzae* This infection occurs through inhalation of fungal spores

Mucormycosis: Mucormycosis caused by group of molds called mucormycetes also known as black fungus which is rare but dangerous infection

How mucormycosis spread?



People get mucormycosis when they comes in contact with fungal spores in environment

For example – mainly lung and sinus form of infection caused when someone breaths in spores

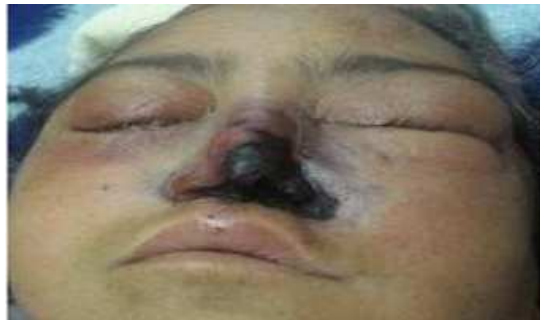These form of mucormycosis mainly usually occurs in people who have health problems or who take medicines which lowers body's ability to fight germs and sickness mainly who suppress immune system These infection also develops on skin after fungus enters the skin through cut , scrape, burn or other type of skin trauma

- Mucormycosis does not spread from people to people
- Fungi which causes mucormycosis
- Rhizopus species
- Mucor species
- Rhizomucor species
- Syncephalastrum species
- Cunninghamella species
- Lichtheimia(formerly absidia)species

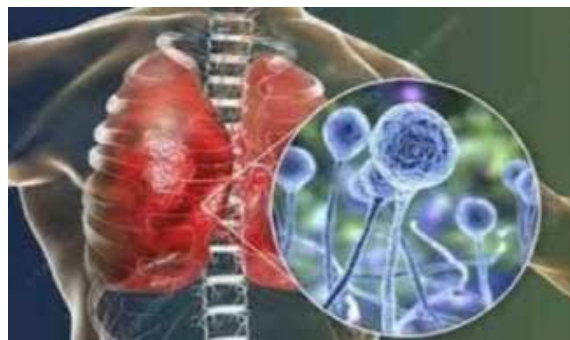
Types of Mucormycosis-

1. 1)Rhinocerebral (sinus and brain) mucormycosis
2. 2)Pulmonary (lung) mucormycosis
3. 3)Gastrointestinal mucormycosis
4. 4)Cutaneous (skin) mucormycosis
5. 5)Disseminated mucormycosis

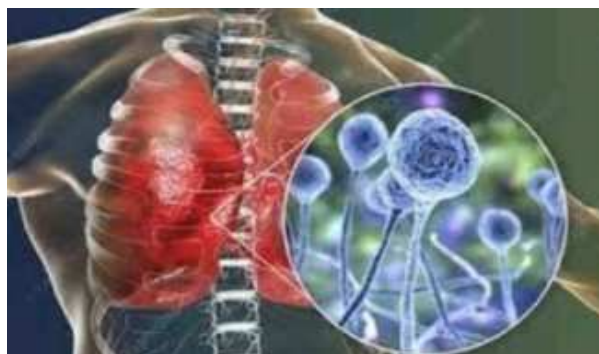
1) Rhinocerebral (sinus and brain) mucormycosis



Rhinocerebralmucormycosis is the infection in the sinus that can spread to the brain. This type of mucormycosis is commonly seen in people who already suffers from uncontrolled diabetes and who had kidney transplant. This type of infection rapidly results in death



2) Pulmonary (lung) mucormycosis

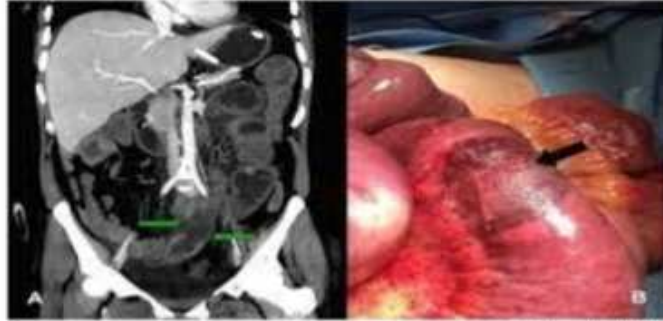

This infection is recognised as secondary complications of COVID-19.

This type of mucormycosis mainly occurs in lungs

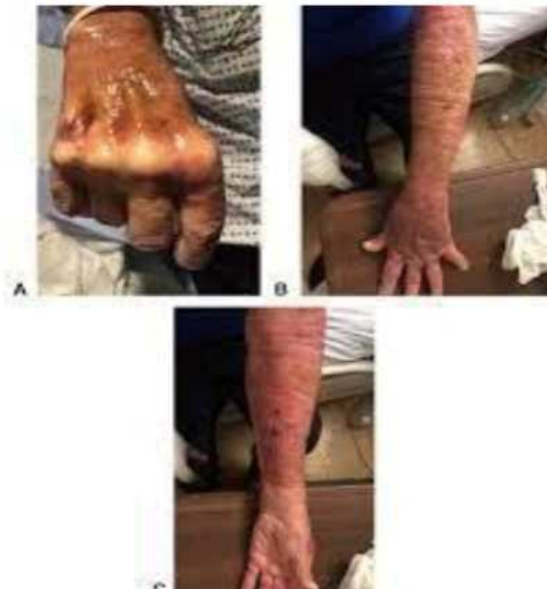This type of infection commonly seen in people with cancer and in people who have had an organ transplant or a stem cell transplant

3) Gastrointestinal mucormycosis



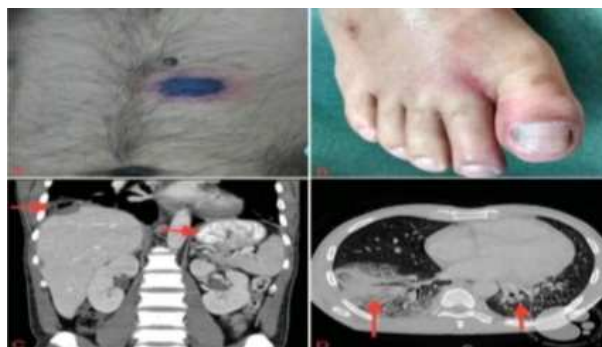This is most common type of infection occurs mainly in young children than adults mainly premature and low birth weight infants less than 1 month of age also seen in people who have had antibiotic, surgery on medication that lowers body ability to fight germs and sickness

4) Cutaneous (skin) mucormycosis



This type of infection mainly causes when fungi enters into the skin through break in skin for e.g. After surgery, burn, or other type of skin trauma. These is most common form of mucormycosis found also in peoples who do not have weakened immune system

5) Disseminated Mucormycosis:



These type of mucormycosis occurs when infection spread through bloodstream to affect another body parts it mainly affects brain but also can affects other organs such as spleen ,heart and skin

Causes of mucormycosis

Various conditions are responsible for mucormycosis infection which are as follows:

- Low oxygen level (hypoxia)
- High glucose level (diabetes, new onset hyperglycemia, steroid induced hyperglycemia)
- Acidic medium (metabolic acidosis, diabetic ketoacidosis)
- High iron level
- Decreased phagocytic activity of white blood cells (WBC) which is due to immunosuppression
- (SARS-COV-2 mediated, steroid mediated, or background comorbidities)
- Prolonged hospitalization with or without mechanical ventilators

Pathogenesis of mucormycosis

Mucormycosis is the lifethreatening infections which generally occurs in patients who are immunocompromised because of various reasons such as diabetic ketoacidosis, increased serum level of iron, organ transplantation. Number of peoples are at risk because of this deadly infection which is caused due to increased prevalence of diabetes mellitus, cancer, organ transplantation. To treat this infection new strategies are urgently needed proper understanding of the pathogenesis of mucormycosis and the host response will provide better novel therapeutic interventions

Host defense against mucormycosis at higher risk according to the clinical and experimental data. For example – individuals who have severe neutropenia are at higher risk for developing mucormycosis. In contrast of this persons suffering with AIDS are not at risk of developing mucormycosis so the neutrophils, not necessarily T lymphocytes are plays important role in inhibiting fungal spore proliferation. By generating oxidative metabolites and cationic peptides the both mononuclear and polymorphonuclear phagocytes kills Mucorales. In the presence of low PH and hyperglycemia phagocytes are dysfunctional and causes defective intracellular killing by both oxidative and nonoxidative mechanism

STEROIDS IN TREATMENT OF COVID-19

Steroids are artificial or man-made version of chemicals which works similar to natural hormone which are present in our body. When they are produced naturally they are called as natural steroids Or when they are produced medically it is called as synthetic steroids.

Steroids are generally reduce the inflammation which are caused when body's own natural immune system tries to fight any virus, infection or any bacteria. Steroids only give relief to patients by reducing inflammation in body but it cannot cure the condition.

Body's reactions when steroids are taken

Inflammation is the body's natural response to towards any infection, bacteria or virus. To fight with this bacteria or virus immune system will show some signs such as swelling b, redness, heat or acute pain in particular part of our body. Some of patients have balanced immune response but some patients have immune response which is dis regulated and which cause inappropriate inflammation. Basically Steroids does not cure illness but gives temporary relief and it work only when it given in right amount or dosage

Steroids and covid-19

If steroids are not given in right time or in right amount they can do more harm to your body .in case of covid-19 86 percent people heal on their own because their natural immunity will take care of disease

Adverse effects of steroids

Steroids can actually cause more harm to our body because it disturbing the natural immune response of the body and also lowered body's defense mechanism which may leads to develop secondary infection For example- mucormycosis which is caused in immunocompromised condition because Steroids lowers the body's natural immune response. The people who are fighting with corona virus leads to compromised and weakened immune system which may have higher chances of developing mucormycosis.

Use of steroids drugs to treat covid-19 set stage for mucormycosis

Steroids drugs are useful in reducing mortality (death rate) in covid-19 patients which has low oxygen saturation level. Steroids generally reduce inflammation but they can negatively affects on the body's natural ability to fight with infection So it is important to to get right dose of steroids if it is not taken in appropriate amount then there are higher chances of contracting another infection. If covid patients have uncontrolled blood sugar and also they are using steroids on top of that then their blood sugar is going to be very high level and high blood sugar leads to acidic blood. Anyone who have Suppressed immune system is at risk for mucormycosis

Mechanisms of action of corticosteroid in COVID- 19

Corticosteroid have pleiotropic effect. Glucocorticoid have anti-inflammatory action which exert by stimulating synthesis and release of anti-inflammatory proteins and also by inhibiting pro inflammatory proteins. Glucocorticoid binds to glucocorticoid receptors (GR). Glucocorticoid receptors present in cytoplasm of almost all cells. When glucocorticoid binds to glucocorticoid receptors, the glucocorticoid receptors dissociates from chaperone proteins heat shock protein 70 (Hsp70) Hsp90, and immunophilin. After that it enters into nucleus to interact with specific DNA sequence

(glucocorticoid responsive elements) of regulatory region of target genes with subsequent chromatic remodeling. Activated glucocorticoid receptors inhibits histone acetyltransferase and activate histone deacetylase which represses expression of pro inflammation. The expression of interferon regulatory factor 3 (IRF3) transcription factor is regulated by glucocorticoid . The GR- glucocorticoid complex inhibit production of pro- inflammatory proteins. Glucocorticoid prevents leucocyte recruitment by suppressing production of acute phase reactants and chemokines. As India fights covid-19 the deadly second wave so names of many steroids have now commonly known Some of the steroids are effective in curing severe or moderate cases of covid-19 patients who requires oxygen or ventilators support. According to expert these steroids are only effective if and only if they are given in right dosage and at the time. Recently addressing the media on the rise of black fungus cases in the Which the misuse of steroids is main reason behind the rise of cases of mucormycosis during post COVID recovery.

Symptoms Of Mucormycosis-

I. Rhinocerebralmucormycosis –

- One sided facial swelling
- Fever
- Nasal congestion
- Headache
- Black lesions on nasal bridge or upper inside of mouth that quickly become more severe

II. Pulmonary mucormycosis

- Fever
- Cough
- Shortness of breath
- Chest pain

III. Gastrointestinal mucormycosis

- Abdominal pain
- Nausea
- Vomiting
- Gastrointestinal bleeding

IV. Cutaneous (skin) mucormycosis

- Infected area may turns black
- Pain
- Warmth
- Excessive redness
- Swelling around the wound

V Disseminated mucormycosis

- Develop mental status changes
- Coma

Treatment Of Mucormycosis-

Antifungal agents - Amphotericin B, isavuconazole, posaconazole

Polyenes - Amphotericin B

Amphotericin B belongs to the polyene class of antifungal drugs. It shows excellent activity against the mucorales in several in vitro studies. Amphotericin B deoxycholate is the only antifungal drug which is approved by US Food and Drug Administration for the treatment of mucormycosis however the d-AmB is nephrotoxic so another liposomal AmB is formulated which is less toxic In the largest review the people treated with d-AmB shows response rate 61% while people treated with liposomal amphotericin B shows 69% response rate . The other lipid formulation of AmB used for treatment of mucormycosis is ABLC.

Mechanism of action

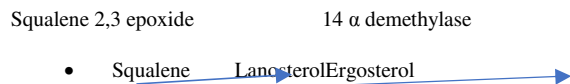
Ergosterol is the component of fungal cell membrane Amphotericin B binds with this ergosterol and forms the spores which causes the leakage of monovalent intracellular ions (K^+ , Na^+ , H^+ and Cl^-) which causes the death of fungal cell. The ergosterol present in fungal cell membrane is the principle site of action for Amphotericin B.

II. Azoles - Posaconazole, isavuconazole

Posaconazole is found to be useful against the mucormycosis. As compared to itraconazole and Isavuconazole, Posaconazole has enhanced in vitro activity . Fungicidal activity of Posaconazole has been demonstrated against Rhizopus and Mucor spp. Posaconazole prolonged the survival and reduce tissue burden in mucor infection and it is effective as standard AmB at highest dose level.

Mechanism of action

Azoles



Lanosterol is formed from squalene with the help of enzyme squalene 2,3 epoxide. Then ergosterol is formed from lanosterol with the help of enzyme 14 α demethylase. Ergosterol is the main component of fungal cell wall. Azoles inhibit the enzyme 14 α demethylase which is needed for ergosterol synthesis and due to inhibition of this enzyme ergosterol is not formed which eventually leading to death of fungal cell.

Intravenous - Amphotericin B, posaconazole, isavuconazole

Orally - posaconazole, isavuconazole

Other antifungal drugs such as fluconazole, voriconazole, echinocandin do not work against fungi that cause mucormycosis.

Role of surgery

The mucormycosis results in formation of thrombosis, tissue infection and necrosis which may affect the penetration of antifungal agents at the site of infection. In severe cases doctor may recommend surgery to remove infected or dead tissue to stop the fungus from spreading this may include removing various parts such as nose, eyes but it is crucial to treat this life-threatening disease. The role of surgery and its timely performance supported in treatment of mucormycosis. In case of rhino-orbito-cerebral disease the surgery before disease progression to cerebral structure improves the chances of successful treatment. In this case survival rate was higher in patients who start treatment within two weeks following the start of symptoms compared with those who delayed in diagnosis.

Other treatments

- Adjunctive treatment with deferasirox or deferiprone
- Adjunctive treatment with hyperbaric oxygen
- Adjunctive cytokines

Diagnosis Of Mucormycosis-

The diagnosis of mucormycosis is the challenging task and treatment should be started as early as possible there is no any circulating antigen detection test is available for diagnosis of mucormycosis. And there is no any standardized blood polymerase chain reaction (PCR) test is available therefore analysis of biological specimen from clinically involved sites is mandatory for diagnosis.

While diagnosing mucormycosis the symptoms, medical history, physical examination and laboratory test are considered. For diagnosis of mucormycosis in case of sinus and lung mucormycosis healthcare professionals collect sample of fluid from respiratory system and then send it in the laboratory for diagnosis.

Tissue biopsy is another option in which small sample of affected tissue is collected and analyzed in laboratory for evidence of mucormycosis under a microscope. But unfortunately this is often difficult in patients who have hematological malignancies because of severe thrombocytopenia. In case if biopsy is not possible then other available specimens such as sputum should be used for examination. For sinusitis sinus biopsies are required. In case of ear, nose and throat endoscopy should be performed. In pulmonary case if sputum smear analysis is negative then broncho-alveolar lavage or pulmonary biopsies should be performed depending upon CT scan the material taken from biopsies should be carefully handled or managed because it may be crushed because zygomycetes are fragile and because of this culture may remain negative.

Depending on the infection the imaging tests are also performed such as CT scan for lung, sinus and other body parts.

- Rhino-orbito-cerebral diagnosis
- MRI-PNS with brain contrast study for ROCM
- Endoscopic collection of debrided tissue /biopsy
- KOH, LPCB, PAS staining
- Pulmonary mucormycosis diagnosis
- Chest X-ray or HRCT
- Repeated negative galactomannan and beta-D-glucan test
- Transbronchial biopsy
- CT guided biopsy from lung
- Prevention and control of Mucormycosis-
- Diabetes and diabetic ketoacidosis should be controlled
- Reduce steroids uptake (if patient is still on) with aim to discontinue rapidly
- Discontinue immunomodulating drugs
- Antifungal prophylaxis not needed
- Extensive Surgical Debridement – to remove all necrotic materials
- Medical treatment
- Install peripherally inserted central catheter (PICC Line)

Management of mucormycosis in covid-19 patients

- Keep the doctor informed about all your co-morbidities such as heart disease, diabetes, hypertension, or any malignancy.
- Tell the doctor about all the medicines which are taken especially any immunosuppressant drug which are taken for any immune disorder
- Always use mask and keep personal hygiene
- Immediately inform to doctor if you observe any of symptoms such as blocked nose with nasal discharge, eye swelling or any difficulty in vision facial pain/numbness, discoloration around mouth nose or eye.
- Don't self-medicate or do not take steroids on your own ✓ Don't ignore the warning signs of this disease.

CONCLUSION:

Mucormycosis is a highly invasive and rapidly progressing form of fungal infection that can be fatal. Although rare, indolent disease course of this infection has been reported.

REFERENCES

1. Annane D. Corticosteroids for COVID-19. *Journal of Intensive Medicine*.
2. Skiada A, Lanternier F, Groll AH, Pagano L, Zimmerli S, Herbrecht R, Lortholary O, Petrikos GL. Diagnosis and treatment of mucormycosis in patients with hematological malignancies: guidelines from the 3rd European Conference on infection in Leukemia (ECIL3). *Hematological*. 2013 Apr; 98(4):492.
3. Mehta S Pandey A Rhino-orbital mucormycosis associated with COVID-19. *Cureus*. 2020 Sep;12(9).
4. Bhat I, Beg MA Athar F. A contemporary intimidation for COVID-19 patients coinfecting with mucormycosis in India. *J Bacterial Mycol Open access*. 2021;9(2):69-71
5. Tabarsi P, Khalili N, Pourabdollah M, Sharifynia S Naeini AS, Ghorbani J, Mohamadnia A, Abtahnia Z, Askari E. COVID-19 association rhinosinusitis mucormycosis due to *Rhizopus* spp.: A rare but potentially fatal infection occurring after treatment with corticosteroids.
6. Suganya R, Malathi N, Karthikeyan V, Janagaraj VD. Mucormycosis: a brief review. *J Pure Appl Microbiol*. 2019;13(1):161-5.
7. Pilmis B, Alanio A, Lortholary O, Lanternier F. Recent advances in the understanding and management of mucormycosis. *F1000Research*. 2018;7.
8. Shevade DS. Mucormycosis : Black fungus , A Deadly Post-COVID Infection. *Microbiology*. 2021;2:1
9. Chatterjee, N, Saha B, Pal J. Mucormycosis in COVID scenario.
10. Garg D Muthu V, Sehgal IS, Ramachandran R, Kaur H, Bhatta A, Puri GD, Chakrabarti A, Agarwal R. Coronavirus disease (Covid-19) associated mucormycosis (CAM): case report and systematic review of literature. *Mycopathologia*. 2021 Feb 5:1-0.
11. Alekseyev K, Didenko L, Chaudhry B. Rhinocerebral mucormycosis and COVID-19 pneumonia. *Journal of medical cases*. 2021 Mar; 12(3):85.
12. Szarpak L. Mucormycosis – a serious threat in the COVID-19 pandemic ? *The journal of Infection* .2021 May 21.
13. Maini A, Tomar G, Khanna, Kini Y, Mehta H, Bhagyashree V. Sino-orbital mucormycosis in a COVID-19 patient: A case report. *International Journal of Surgery Case Reports* .2021 May 1;82:105957.
14. Singh AK, Singh R, Joshi SR, Misra A. Mucormycosis in COVID-19 :A systematic review of cases reported worldwide and in India . *Diabetes and Metabolic Syndrome : Clinical Research and Reviews*. 2021 May 21.
15. Johnson AK, Ghazarian Z, Cendrowski KD, Persichino JG. Pulmonary aspergillosis and mucormycosis in a patient with COVID-19 . *Medical mycology case reports*. 2021 Jun 1;32:64-7.