



A Review on Progeria a Rare Genetic Premature Ageing Disorder

¹Shaikh Sumaiyya Wahaj, ²Mali Shubhangi

^{1,2}Pratibhatai Pawar College of Pharmacy, Shirampur.

Abstract :-

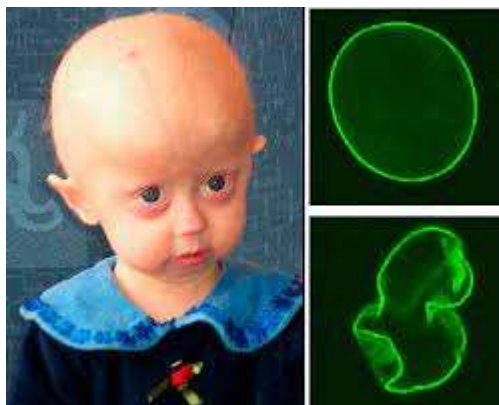Progeria or Hutchinson–Gilford progeria syndrome is a rare genetic disorder characterized by dramatic premature aging and accelerated cardiovascular disease. It is almost never passed on from parent to child. Progeria is almost always caused by de novo point mutation in the lamin A gene that activates a cryptic splice donor site, producing a truncated mutant protein termed “progerin.” Progeria shows characteristic facial appearance including prominent eyes, thin nose with a beaked tip, thin lips, a small chin, and protruding ears, severe hardening of the arteries beginning in childhood. In the past, doctors had to base a diagnosis of progeria solely on physical symptoms but progeria research foundation establishes the Progeria cell and tissue bank to assist in further research and diagnostic process. Aspirin may help prevent atherothrombotic events, stroke and heart attacks by hindering platelet aggregation. Vitamin supplementation, Fluoride supplements are recommended. A Study of Zoledronic acid, Pravastatin, and Lonafarnib for Patients with Progeria is ongoing, it is under phase II.

Keywords :- Progeria, Progerin, Aspirin, Pravastatin, Atherothrombotic

Introduction

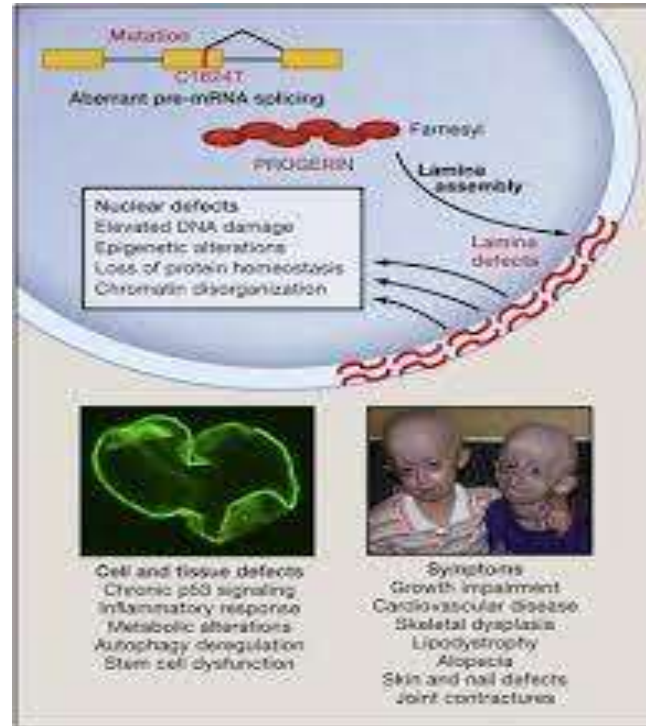
The first study of progeria to be described in medical literature was that of Hutchinson in 1886, under the title of 'Congenital Absence of Hair and Mammary Glands.' Hastings Gilford recognizing this condition as a clinical entity, described a case of his own and re-described Hutchinson's original case. He introduced the term progeria (post prematurely old). The term "progeria," coined by Gilford in 1904, is used to describe. Children with the appearance of premature aging or senility. The word progeria comes from the Greek words "pro" meaning "before" or "premature", and "gēras" meaning "old age". Progeria is an extremely rare autosomal dominant genetic disorder in which symptoms resembling aspects of aging are manifested at a very early age. Progeria is one of several progeroid syndromes [2–4]

Those born with progeria typically live to their mid-teens to early twenties.[5,6] It is a genetic condition that occurs as a new mutation, and is rarely inherited, as carriers usually do not live to reproduce. Although the term progeria applies strictly speaking to all diseases characterized by premature aging symptoms, and is often used as such, it is often applied specifically in reference to Hutchinson–progeria syndrome (HGPS). A prominent physical feature of progeria is marked outward protrusion of the ears (pinna) and absence of ear lobes, yet there is a general consensus observed that hearing in children with progeria is not impaired, at least by clinical examination. According to James W. Hall James C. Denny [8] documented Characteristics of the Progeria Syndrome General (Short stature, Decreased weight for height, Incomplete sexual maturation) Skin (Diminished subcutaneous fat ;Thin, dry, wrinkled skin Prominent superficial veins) Head (Craniofacial disproportionate size, Anterior fontanelle patent, Beaked nose ,Micrognathia, Thin lips, Prominent eyes, Protruding ears, Absent earlobes, "Plucked bird" appearance) Hair(Alopecia (hair loss) Absent eyebrows and eyelashes) Teeth (Dentition delayed and abnormal (crowding) Trunk and Limbs(Pear-shaped thorax ,Short clavicles ;Wide-based, shuffling gate Thin limbs ,Dystrophic finger nails (brittle, yellowish, curved) Radioluscent terminal phalanges Prominent and stiff joints). But Not all characteristics are consistently present The condition is estimated to affect 1 in 4 million newborns .



A Short History of HGPS :-

HGPS was first described by Drs. Jonathan Hutchinson and Hastings Gilford in 1886 and 1897, respectively. For more than 100 years, its cause was a medical mystery. The disease was designated as a premature aging syndrome by Gilford based on the overall resemblance of patients to aged individuals and the presence of aging-associated symptoms, including lack of subcutaneous fat, hair loss, joint contractures, progressive cardiovascular disease resembling atherosclerosis, and death due to heart attacks and strokes in childhood.



HGPS: From Genetics to symptoms :-

HGPS is caused by a spontaneous point mutation in the LMNA gene, coding for the nuclear intermediate filament proteins lamin A and C. The disease mutation activates an alternative pre-mRNA splice site in exon 11 that results in removal of 150 nt from the 3' end of this exon and creates an internal deletion of 50 aa in the translated lamin A protein. The mutant protein (red), referred to as progerin, is permanently farnesylated as the 50 aa deletion includes an endoproteolytic cleavage site, which normally removes the farnesylated C terminus from the wild-type protein. The farnesyl group is believed to facilitate the association of the protein to the nuclear membrane, resulting in its accumulation at the nuclear periphery. Association of progerin with the lamina interferes with normal lamina function and triggers, via yet unknown mechanisms, many of the commonly observed nuclear defects. HGPS cells also exhibit nonnuclear defects, including altered signaling and metabolic properties. It is assumed that these cellular defects and particularly the loss of stem cell function contribute to the prominent overt patient symptoms. (Left) Fluorescently tagged progerin (green) accumulates at the periphery of patient nuclei and alters nuclear morphology.

Two progeria patients. Image reproduced with permission, courtesy of The Progeria Research Foundation. The mapping of the disease gene revealed that HGPS is a sporadic, autosomal dominant disease caused by a mutation in LMNA (De Sandre-Giovannoli et al., 2003; Eriksson et al., 2003). This gene codes for the inner nuclear membrane proteins lamins A and C, two prominent structural components of the eukaryotic cell nucleus. HGPS is a member of a group of diseases called laminopathies, resulting from mutations throughout the LMNA gene that result in a wide spectrum of overlapping disorders. These include muscular dystrophies, a peripheral neuropathy, lipodystrophy syndromes, and accelerated aging disorders. The disease-causing mutation in HGPS activates what is normally a only sporadically used alternative splice site in LMNA exon 11, resulting in partial deletion of the exon. Although the discovery of disease genes does not always inform about disease mechanism, the identification of an LMNA mutation as the cause of HGPS inspired intense basic and clinical research into this disease and its relationship to aging. The reason for the rapid progress in our understanding of HGPS was that the gene identification dovetailed with extensive prior work by basic cell biologists on the complex posttranslational processing events of lamin A, which would turn out to be key for understanding the HGPS disease mechanism.

Normally, lamin A is produced via a prelamin intermediate whose C-terminal cysteine residue is first modified by farnesylation and carboxymethylation followed by enzymatic cleavage of the terminal 15 amino acids, including the farnesylated cysteine, by the ZMPSTE24 endoprotease. However, in the HGPS mutant prelamin A isoform, this cleavage site is missing as a result of the aberrant splicing event. Thus, the HGPS mutation leads to the

accumulation of a permanently farnesylated, uncleaved lamin A isoform named progerin . This aberrantly modified, lamin A intermediate triggers, by yet-to-be discovered mechanisms, the many cellular and organismal disease symptoms.

Causes :-

Hutchinson-Gilford syndrome (HGPS) is an extremely rare autosomal dominant genetic disorder in which symptoms resembling aspects of aging are manifested at a very early age.. Its occurrence is usually the result of a sporadic germline mutation; although HGPS is genetically dominant, sufferers rarely live long enough to have children, preventing them from passing the disorder on in a hereditary manner.[12]

HGPS is caused by mutations that weaken the structure of the cell nucleus, making normal cell division difficult. The histone mark H4K20me3 is involved and caused by de novo mutations that occur in a gene that encodes lamin A. Lamin A is made but is not processed properly. This poor processing creates an abnormal nuclear morphology and disorganized heterochromatin. Patients also do not have appropriate DNA repair, and they also have increased genomic instability.[13]

In normal conditions, the LMNA gene codes for a structural protein called prelamin A, which undergoes a series of processing steps before attaining its final form, called lamin A. Prelamin A contains a "CAAX" where C is a cysteine, A an aliphatic amino acid, and X any amino acid. This motif at the carboxyl-termini of proteins triggers three sequential enzymatic modifications. First, protein farnesyltransferase catalyzes the addition of a farnesyl moiety to the cysteine. Second, an endoprotease that recognizes the farnesylated protein catalyzes the peptide bond's cleavage between the cysteine and -aaX. In the third step, isoprenylcysteine carboxyl methyltransferase catalyzes methylation of the carboxyl-terminal farnesyl cysteine. The farnesylated and methylated protein is transported through a nuclear pore to the interior of the nucleus. Once in the nucleus, the protein is cleaved by a protease called zinc metallopeptidase STE24 (ZMPSTE24), which removes the last 15 amino acids, which includes the farnesylated cysteine. After cleavage by the protease, prelamin A is referred to as lamin A. In most mammalian cells, lamin A, along with lamin B1, lamin B2, and lamin C, makes up the nuclear lamina, which provides shape and stability to the inner nuclear envelope. Before the late 20th century, research on progeria yielded very little information about the syndrome. In 2003, the cause of progeria was discovered to be a point mutation in position 1824 of the LMNA gene, which replaces a cytosine with thymine. This mutation creates a 5' cryptic splice site within exon 11, resulting in a shorter than normal mRNA transcript. When this shorter mRNA is translated into protein, it produces an abnormal variant of the prelamin A protein, referred to as progerin. Progerin's farnesyl group cannot be removed because the ZMPSTE24 cleavage site is lacking from progerin, so the abnormal protein is permanently attached to the nuclear rim. One result is that the nuclear lamina does not provide the nuclear envelope with enough structural support, causing it to take on an abnormal shape.[16] Since the support that the nuclear lamina normally provides is necessary for the organizing of chromatin during mitosis, weakening of the nuclear lamina limits the ability of the cell to divide. However, defective cell division is unlikely to be the main defect leading to progeria, particularly because children develop normally without any signs of disease until about one year of age. Farnesylated prelamin A variants also lead to defective DNA repair, which may play a role in the development of progeria. Progerin expression also leads to defects in the establishment of fibroblast cell polarity, which is also seen in physiological aging.

Mutation in lamin a cause Progeria :-

Originally thought to be an autosomal-recessive disorder, more recent evidence has identified the genetic basis for progeria to be a single nucleotide mutation with autosomal dominant expression. Lamins are type V intermediate filament proteins and have a short N-terminal "head" domain, an alpha-helical "central rod" domain, and a globular tail domain. Lamins are classified as either A or B type according to their primary sequence, expression pattern, and biochemical properties. B-type lamins are expressed in all cells during development and in adult animals, whereas A-type lamins are expressed in differentiated cells. The LMNA gene encodes three A-type lamins: lamin A (LA), lamin C, and lamin A delta-10. Lamin A contains a C-terminal CAAX box, which undergoes methyl esterification and farnesylation. In the process of LA maturation, the C-terminal 18 residues, which include the modified C-terminal cysteine, are removed in two specific cleavage steps. The most frequent LMNA mutation in Hutchinson-Gilford progeria syndrome is a nucleotide substitution at position 1824, C-to-T, resulting in a silent gly-to-gly mutation at codon 608 (G608G) within exon 11 of the LMNA gene. This predicts a deletion of 50 basepairs.

STEPS IN NORMAL CELL	STEPS IN PROGERIA CELL
The gene LMNA encodes a protein called prelamin A	The gene LMNA encodes a protein called prelamin A
Prelamin A has a farnesyl group attached to its end	Prelamin A has a farnesyl group attached to its end
Farnesyl group is removed from prelamin A	Farnesyl group remains attached to prelamin A
Normal form called PRELAMIN A	Abnormal form of prelamin A called PROGERIN
Prelamin A is not anchored to the nuclear rim	Progerin is anchored to the nuclear rim
Normal state of the nucleus	Abnormally shaped nucleus

In addition, Hutchinson-Gilford progeria syndrome cell nuclei frequently display irregular shapes. In normal conditions, the LMNA gene encodes a protein called prelamin A, which leads to the lamin A form. There is a farnesyl group attached to the carboxyl-terminus of its structure. Farnesyl molecule allows prelamin A to be anchored to nuclear rim, and then it is removed. Before the late 20th century, research on progeria yielded very little information about the syndrome. In 2003, the cause of progeria was discovered to be a point mutation in position 1824 of the LMNA gene, replacing cytosine with thymine, creating a truncated form, progerin, of the prelamin A protein whose further processing is abnormal. Normal lamin A is a major structural protein of the nuclear lamina of the nucleus (along with lamin C); when LMNA is mutated, farnesyl group cannot be removed and progerin does not integrate into this structure and accumulates, disrupting it. This is when HGPS appears. Since the nuclear lamina participates in organizing chromatin and supporting the nuclear envelope; this disrupts the human cell nucleus as a whole, limiting the ability of the cell to divide. Then, the appearance of affected nuclei is like bubbles or a cluster of grapes. Progerin may also play a role in normal human aging, since its production is activated in senescent wild type cells.

Notable cases :-

Yan Hui, a student of Confucius, aged rapidly and died at a young age, appearing as an old man by his late 20s. He may be one of the earliest potential examples of progeria in history.

In 1987, fifteen-year-old Mickey Hays, who had progeria, appeared along with Jack Elam in the documentary *I Am Not a Freak* Elam and Hays first met during the filming of the 1986 film *The Aurora Encounter*, in which Hays was cast as an alien. The friendship that developed lasted until Hays died in 1992, on his 20th birthday. Elam said, "You know I've met a lot of people, but I've never met anybody that got next to me like Mickey."

Harold Kushner's 1978 book *When Bad Things Happen to Good People*, which explores God and the problem of evil, was written in response to his 14-year-old son's death due to progeria.

Margaret Casey, a 29-year-old progeria victim who was then believed to be the oldest survivor of the premature aging disease, died on Sunday, May 26, 1985. Casey, a freelance artist, was admitted to Yale-New Haven Hospital on the night of May 25 with respiratory problems, which caused her death.

Sam Berns was an American activist with the disease. He was the subject of the HBO documentary *Life According to Sam*. Berns also gave a TEDx talk titled *My Philosophy for a Happy Life* on December 13, 2013.

Hayley Okines was an English progeria patient who spread awareness of the condition.

Rania was a French progeria victim who died on October 16, 2020, at the age of 16. She was a popular creator on the social media platforms TikTok, Instagram and YouTube with 871,000 followers on TikTok, 700,000 on Instagram and 320,000 on YouTube.

Leon Botha, the South African painter and DJ who was known, among other things, for his work with the hip-hop duo *Die Antwoord*, lived with progeria.[71] He died in 2011, aged 26.

Tiffany Wedekind of Columbus, Ohio, is believed to be the oldest survivor of progeria at 43 years old as of 2020.

Alexandra Peraut is a Catalan girl with progeria, she has inspired the book *Una nena entre vint milions* ('A girl in 20 million'), a children's book to explain progeria to youngsters. Adalia Rose Williams (born December 10, 2006), an American girl with progeria, was a notable YouTuber and vlogger who shared her everyday life on social media. She died on January 12, 2022, at the age of 15.

Epidemiology :-

As of now, the prevalence of this syndrome is one in 4 - 8 million new births². Incidence of progeria is uniform throughout the world showing no gender, geographical or ethnic predisposition, and hence mostly considered as sporadic. Presently, there are about 114 children across 39 countries diagnosed

with HGPS2 . The average age of survival is 13.5 years (with life expectancy about 8 - 21 years) and death occurs due to stroke, myocardial infarction³ , heart failure or atherosclerosis (cardiovascular disease). Of the clinical symptoms of various PSs like growth retardation, skin atrophy, alopecia, lipodystrophy, osteolysis and an augmented susceptibility for malignant tumours, the notable thing in HGPS is that the cognitive abilities remain unaffected. Classical HGPS is usually caused by a sporadic autosomal dominant mutation (except unique inheritable variety such as Werner's syndrome). There are a few atypical forms of progeria, also called non-classical progeria in which growth is less retarded, scalp hair fall off slowly, progression of lipodystrophy is delayed, osteolysis is more visible with exception in face and survival is observed mostly till adulthood. Nonclassical HGPS follows autosomal recessive pattern of inheritance. Mostly, HGPS occurs as a result of a de novo point mutation in the DNA⁷ . These children look normal and healthy at birth but in due course of time (mostly within a year) they gain very less weight due to growth failure. By the age of one and a half to two years, they are thin with small face and abnormal jaw size relative to the size of head, have high-pitched voice, irregular dentition, a pinched nose and notably big wide-open eyes, undersized dystrophic clavicles and absence of sexual maturation⁸ . Body fat and eyelashes are progressively lost and hair start becoming thinner and fall off, finally to become completely bald (alopecia). The skin becomes very thin, delicate and translucent through which veins could be seen. Complaints of angina, high blood pressure, stiffness of joints and hip dislocation are also common. Clinical findings show that these patients show prolonged prothrombin time and elevated platelet count which is not seen in normal physiological ageing. The biochemical analyses show normal results except for the increased low-density lipoproteins and cholesterol levels in the serum and increased urinary excretion of hyaluronic acid (HA) in these patients.

As an estimate, these children biologically age about ten years in a single year. One remarkable thing is that they have normal IQ and intelligence. Till date, not many studies have been done to evaluate various signaling pathways or neurochemical profile in the brain of such subjects. Therefore, the involvement of brain signaling pathways in the pathogenesis of the disease cannot be ruled out. Advancement of heart disease occurs at an exceptionally accelerated rate in these children at the age of around 13 years which is comparable to the prevalence in normal population around the sixth decade or so. Only a single report of the survival of a patient up to 45 years has been reported.

Signs and Symptoms :-

We study certain number of paper about progeria and find out symptoms of progeria. Children with progeria usually develop the first symptoms during their first few months of life. The earliest symptoms may include a failure to thrive and a localized scleroderma-like skin condition. As a child ages past infancy, additional conditions become apparent usually around 18–24 months. Limited growth, full-body alopecia (hair loss), and a distinctive appearance (a small face with a shallow recessed jaw, and a pinched nose) are all characteristics of progeria. Signs and symptoms of this progressive disease tend to become more marked as the child ages. Later, the condition causes wrinkled skin, atherosclerosis, kidney failure, loss of eyesight, and cardiovascular problems.

Scleroderma, a hardening and tightening of the skin on trunk and extremities of the body, is prevalent. People diagnosed with this disorder usually have small, fragile bodies, like those of elderly people. The face is usually wrinkled, with a larger head in relation to the body, a narrow face and a beak nose. Prominent scalp veins are noticeable (made more obvious by alopecia), as well as prominent eyes. Musculoskeletal degeneration causes loss of body fat and muscle, stiff joints, hip dislocations, and other symptoms generally absent in the non-elderly population. Individuals usually retain typical mental and motor development . Literature study design of the causes of the Progeria done from different published journals, newspapers, google onlines and from other sources are given below.



Potential treatment of HGPS :-

Prior to the HGPS gene discovery, treatments were limited and unsuccessful. For instance, nutritional and growth hormone therapy resulted in only transient improvements in individuals with HGPS. PrelaminA, Isoprenylation and methylation inhibitors Lonafarnib, Zoledronate/Pravastatin, Monoaminopyrimidines and isoprenylcysteine carboxyl methyltransferase inhibitor:

The aberrant splice event that gives rise to progerin leads to the deletion of the ZMPSTE24 cleavage site normally used to remove the farnesylated carboxy terminus from prelamin A during post translational processing. Consequently, permanently farnesylated progerin remains anchored to the inner nuclear membrane resulting in dominant-negative disruption of the nuclear scaffold upon progerin dimerization with wild-type lamins [16]. Knowledge of these steps predicted that blocking farnesylation using farnesyl transferase inhibitor (FTI) drugs would decrease progerin production and toxicity. Blocking farnesylation of progerin with FTIs restored reductions in nuclear blebbing both in transiently transfected HeLa, HEK 293, NIH 3T3 cells and human HGPS fibroblasts [18-21]. In transgenic HGPS murine models treated normal nuclear architecture and resulted in significant bone mineralization, and weight are improved, lifespan is extended and cardiovascular defects are prevented [24]. In 2007, the above studies led to the initiation of a prospective single-arm clinical trial (ClinicalTrials.gov, NCT00425607), using an FTI called lonafarnib, which was originally developed for the treatment of cancer. A cohort of 25 HGPS patients between 3 and 16 years of age were included in this trial and received lonafarnib for a minimum of 2 years. In 2012, researchers reported that some children with HGPS receiving lonafarnib showed a modest improvement in weight gain.

Carlos Lopez-Otin (Spain) demonstrated the synergistic effect of a combination of Zoledronate (N-BisPhosphonate) and PRAvastatin (statin) (ZOPRA) and their effectiveness to reduce prenylation and rescue HGPS cells defects and the progeroid phenotypes of Zmpste24 mice, including improvement of growth retardation, loss of weight, lipodystrophy, hair loss and bone defects. Likewise, the longevity of these mice was substantially extended.

On the other hand, among 21,608 small molecules tested in induced pluripotent stem cell (iPSC) lines derived from HGPS patients, Nissan and colleagues identified several compounds, called monoaminopyrimidines (mono-APs), as new modulators of farnesylation, resulting, in vitro in improved phenotypes associated with HGPS. In addition to isoprenylation, consequence of defective posttranslational modification to prelamin A in progeria was reported implicating the carboxy methylation that is mediated by isoprenylcysteine carboxyl methyltransferase.

Other Progeroid Syndrome :-

Werner syndrome (WS) is a rare PS very similar to HGPS in its clinical symptoms. It is inherited as an autosomal recessive trait. The mutation lies in the WRN gene encoding DNA helicase, located on chromosome 8, which impairs telomere maintenance and further DNA replication in the cell. Individuals with this syndrome develop normally until about 10 years of age and exhibit clinical symptoms in early teenage years. The mean age of survival in WS is 54 years. WS is more prevalent in Japan and in the Italian island of Sardinia than any other part of the world. About 1000 cases are reported in the world; more than 800 of these cases are in Japan. There is another similar and rare premature ageing syndrome known as dyskeratosis congenita (DKC). DKC is an inheritable bone-marrow failure disorder linked to mutations in DKC1, TERC, TERT, NOP10, NHP2, TIN2 or TCAB1 genes, implicating the physiology of telomere.

Trichothiodystrophy (or Tay's syndrome) is an autosomal recessive disease identified by small stature, mental and overall growth retardation, ocular defects, brittle hair and other developmental abnormalities like congenital ichthyosiform erythroderma. Patients have abnormal production of transcription factor II H (TFIIH), a general transcription factor active in basal transcription and nucleotide excision repair, due to mutations in genes encoding any of the 3 subunits of TFIIH—ERCC2 (XPD), ERCC3 (XPB), and GTF2H5 (TTDA).

Cockayne syndrome, another rare congenital disorder, is characterized by growth failure, atypical photosensitivity and importantly impaired development of the nervous system. Mutations in any of the ERCC6 and ERCC8 genes bring about defect in DNA repair mechanism which eventually precipitates this disease. By the age of two years, growth and development of the individual becomes abnormal. The distinctive physical appearance of cachectic dwarfism with sunken eyes, reduction of the skin and hair thickness and an arched standing posture characterizes the ageing process. Neuropathological investigations demonstrate widespread demyelination in the central and peripheral nervous systems of the patients. There is also neuronal loss in the cerebral cortex and cerebellum, and calcification around capillaries in the cerebral cortex and basal ganglia. These children show cognitive impairment and intellectual deficits which often worsen with age. A summary of different PSs with their clinical symptoms has been illustrated in.

Experimental Models Of Progeria :-

In order to develop a better understanding of the pathogenesis and progression of PSs and design potential therapies, effort has been put in by scientists globally to develop animal models of the same. Lmna mice develop cardiac and skeletal myopathic phenotype similar to the Emery-Dreifuss muscular dystrophy in humans. Another study showed that homozygous mice carrying autosomal recessive mutation in Lmna gene have a phenotype resembling HGPS, with marked growth retardation, pathologies of skin and bone and death by 4-5 weeks of age. DNA repair deficient Ercc1^{-/-} mice show a slight retardation in embryonic and early post-natal development, but the growth almost stops in the second post-natal week, leading to death by 4 weeks of age. These Ercc mice exhibit skin, liver and bone marrow pathologies, progressive ataxia and premature ageing. Zmpste2 mice are normal at birth but soon develop progeroid symptoms like alopecia, kyphosis, abnormalities in dentition and bones, etc which improve when treated with protein farnesyltransferase inhibitor (FTI). Zmpste2 mice also exhibit very high circulating levels of growth hormone (GH) and a drastic reduction in plasma insulin-like growth factor 1 (IGF-1). The GH/IGF-1 signaling is known to be crucial for the control of longevity. Recombinant IGF-1 treatment refurbishes

the balance between IGF-1 and GH in mice, delays the onset of many progeroid symptoms and improves their lifespan considerably. In vitro studies also implicate the possible role of FTIs in the treatment of HGPS. A recent study has shown that rapamycin inhibits aberrant mTORC1 signaling in Lmna mice and improves their cardiac and skeletal muscle functions thereby enhancing their survival.

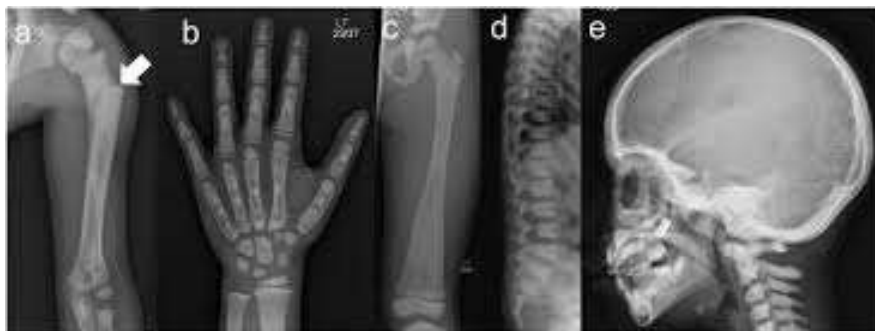Case study -

A 14-year-old girl child presented with progressive history of coarsening of skin, failure to thrive and inability to squat for the past three to four years. The child had also developed global alopecia over the past few years. The perinatal history was uneventful. She was apparently normal till one year of age when the parents started noticing the above features. She had normal intelligence. No family history of similar complaints could be elicited.



General examination revealed the child to be of short stature and malnourished. Eyes appeared prominent with hypoplastic chin. Multiple patches of coarse and thickened skin, especially over the dorsum of the hands and shoulders. The terminal ends of the fingers appeared broad and stubby. Based on the history and clinical findings a provisional diagnosis of progeria was made.

Biochemical investigations were normal except for increased serum cholesterol and increased urinary excretion of hyaluronic acid. To confirm the diagnosis, the child was subjected to a skeletal survey. Radiographs of the skull showed diastasis of the sagittal suture with numerous wormian bones. Radiograph of the mandible showed the hypoplastic mandible with infantile angle. Radiograph of the chest showed sloping ribbon-like ribs with thinning of both third ribs posteriorly. The lateral half of both the clavicles was absent. Radiograph of the dorsal spine in the lateral projection showed presence of fish mouth vertebrae. Pelvis radiograph in AP projection presence of bilateral coxa valga deformity. Radiograph of the hands and feet revealed resorption of terminal phalanges. The bone age however corresponded to the chronological age of the patient. The radiological findings confirmed the clinical diagnosis of progeria.



Discussion :-

Progeria is a genetic disorder rarely encountered and is characterized by features of premature aging. It is also known as “Hutchinson-Gilford Progeria syndrome”. In this syndrome, the rate of ageing is accelerated up to seven times that of normal. The average life span is 13 years (range 7-27 years) occasional survival till the age of 45 years.³ The death is mainly due to cardiovascular complications like myocardial infarction or congestive heart failure.

The probable cause is a mutation in the Lamin located in the nuclear matrix.⁴ Increase in the blood hyaluronic acid levels is responsible for sclerodermatous changes and cardiovascular abnormalities. In progeria, rise in blood and serum levels of low-density lipoprotein and cholesterol and

total lipids is commonly seen. Failure to thrive may be seen possibly due to a bioinactive growth hormone and lack of vasculogenesis caused by excessive excretion of hyaluronic acid.⁵

The affected children are normal at birth and grow normally till about the end of the first year, when both normal growth and gain in weight slow down. At the end of the first decade, the size attained is that of a normal child of three years of age. Loss of hairs and subcutaneous fat along with sclerodermatous changes give rise to characteristic “plucked bird” appearance at about 6-12 months of age. Scalp hair and eyelashes are progressively lost with increased prominence of scalp veins. The affected child is short statured and underweight with an average height of 100 cm and average weight of 12-15 kg or even less.⁶ Progressive degenerative changes occur in the skeleton and blood vessels with advancing age. Delayed eruption and abnormal dentition is also common. The typical “horseriding” stance described in literature is due to the coxa valga deformity. Bone age is normal but mental age may be higher.¹

Skeletal survey of the patients reveals the following radiological features: The calvarium is thin and relatively large and the diploic space is absent or very shallow; the face is small with a disproportionate small mandible that retains its infantile obtuse angle. The ascending rami of the mandible are very short. Closure of the anterior fontanelle is delayed. Vascular markings and wormian bones are conspicuous in the large thin calvaria. The clavicles are small in caliber and rarefied at birth; during childhood they may disappear in part or in toto due to progressive osteolysis and fibrosis. The ribs are abnormally gracile and the posterior segments of the upper four ribs on both sides may also disappear in early childhood. The long bones are shortened and overconstricted in their central segments and demonstrate flares at the ends. Coxa valga deformity may be marked, with the neck continuing in the axis of the femoral shafts; the femoral heads are only partially in their acetabular fossae. The greater trochanters are bizarre in shape and position. Some carpal ossification centers are sclerotic, while others participate in the general osteopenia. There may be a marked delay in the healing of fractures and nonunion. Other features include occasional acro-osteolysis and persistence of anterior vascular channels in vertebral bodies.

The differential diagnosis includes Werner syndrome (WS), Acrogeria, Rothmund-Thomson syndrome (RTS) and Cockayne syndrome (CS). Werner syndrome is also known as progeria adultorum, progeria of the adult and pangeria. It is the most common of the premature aging disorders. The onset might occur in individuals in their mid-teens or it may be delayed until an individual is as old as 30 years. Both sexes are affected equally. Death usually occurs when patients are aged 30-50 years because of atherosclerosis or malignant tumors. Acrogeria is a progeroid syndrome of premature aging of the skin without the involvement of internal organs seen in the Hutchinson-Gilford progeria syndrome. It is seen mainly in females and in the form of sporadic cases. Familial cases are also seen (Gottron type). Acro-osteolysis of the distal phalanges, delayed cranial suture closure with wormian bones, linear lucent defects of the metaphyses and antegonial notching of the mandible are the predominant skeletal features of the disorder.

Rothmund-Thomson syndrome is a hereditary and familial disease characterized by short stature, cataracts, pigmentation of skin, baldness, abnormalities of bones, nails and teeth. Cockayne syndrome spans a spectrum that includes CS Type 1, the classic form; CS Type 2, a more severe form with symptoms present at birth (i.e. cerebrooculofacial-skeletal [COFS] syndrome, Pena-Shokeir Type 2 syndrome); CS Type 3, a milder form; and xeroderma pigmentosa-Cockayne syndrome (XP-CS). Cockayne syndrome Type 1 and Type 2 are autosomal recessive disorders that feature growth deficiency, premature aging and pigmentary retinal degeneration along with a complement of other clinical findings. Type 1 presents at birth, whereas Type 2 appears during early childhood. Fatality usually occurs in early adolescence, but some patients survive until early adulthood.

Current Status Of Diagnosis Drugs And Medication :-

Although the pursuit for finding an effective treatment for HGPS is still on, yet there is still no diagnostic kit available for early detection of the same. Usually in practice, a clinical assessment is done based on the phenotypical evidence and medical history of the child. Following this, a genetic test for LMNA mutation is commonly done for confirming the diagnosis of HGPS to initiate the treatment programmes early in the progression of the disorder. A case report on HGPS has reported that clinical diagnosis can also be established by radiological findings - diastasis of the sagittal suture with several wormian bones in the skull; hypoplastic mandible with infantile angle; the presence of fish-mouth vertebrae; the occurrence of bilateral coxa valga deformity; resorption of terminal phalanges, etc.

A class of cancer drugs known as farnesyltransferase inhibitors (FTIs) has shown promise of reversing the structural abnormalities of the nucleus (associated with build up of prelamin A) which is one of the characteristics of the cells in the HGPS children. As the name suggests, these drugs restrict the activity of farnesyltransferase required to make a liaison between farnesyl groups and progerin proteins. FTIs have shown improvement in many of the features of progeria-like mouse model. Specifically, FTIs improve the nuclear shape in the fibroblasts from the patients of PSs and improve nuclear blebbing in the fibroblasts of mouse model with the gene targeted for HGPS. One study has shown the prevention of both the onset and late progression of cardiovascular disease by a FTI (Tipifarnib) in a transgenic LMNA G608G mouse model of HGPS supporting the use of these drugs. Varela and co-workers have shown prelamin A and its truncated form progerin/LADelta50 to undergo alternative prenylation by geranylgeranyltransferase when the farnesyltransferase was inhibited. This study has tried to explain the low efficiency of FTIs in improving the physical composition of the progeroid mouse models. They further showed that the combination of statins and aminobisphosphonates inhibited both farnesylation and geranylgeranylation of progerin and prelamin A and also improved ageing related phenotype of Zmpste2 mice strikingly. In addition, these extended the longevity of the mice significant.

Western blot -

Analysis of cellular lysates from human fibroblasts was done as follows. Cells were lysed in buffer containing 10 mM Tris-HCl, pH 7.4, 1% Triton X-100, 0.1% SDS, 0.5% sodium deoxycholate, 1 mM NaVO₃, 150 M NaCl, 1 mM EDTA, 1 mM PMSF, 1 μM aprotinin, leupeptin, pepstatin. Proteins were loaded in Laemmli sample buffer and subjected to SDS-PAGE followed by immunochemical reactions. Immunoblotted bands were detected by

enhanced chemiluminescence (Amersham) incubated with PBS containing 4% BSA to saturate non-specific binding. Incubation with primary antibodies was performed overnight at 4°C, while secondary antibodies were applied for 1h at room temperature. Slides were mounted with an anti-fade reagent in glycerol and observed with a Nikon E 600 fluorescence microscope equipped with a digital camera. Pictures were elaborated with Photoshop-6 software.

Immunofluorescence -

Human fibroblasts grown on coverslips were fixed in paraformaldehyde 4% in PBS at 4°C and post-fixed in methanol at -20°C for 7 min. Samples were stained with primary antibodies. Noteworthy improvements: Weight: One in three children demonstrated a greater than 50 percent increase in annual rate of weight gain, or switched from weight loss to weight gain, because of increased muscle and bone mass. Bone Structure: Bone rigidity improved to normal levels after FTI treatment. Cardiovascular: Arterial stiffness, associated with atherosclerosis, decreased by 35 percent. Vessel wall density also improved. Potential therapeutic effects of mTOR inhibitors: Three classes of mTOR inhibitors have been developed: rapamycin/rapalogs that are allosteric mTORC1 inhibitors; ATP-competitive, 'active-site' mTORC1/mTORC2 inhibitors that target the catalytic site of mTOR.

Rapamycin -

Rapamycin (also known as sirolimus) is a natural compound produced by the bacterium *Streptomyces hygroscopicus* that acts as an allosteric mTORC1 inhibitor. It forms a gain-of-function complex with 12-kDa FKBP12, which binds to the FKBP12/rapamycin-binding (FRB) domain of mTOR only when mTOR is associated with other components of mTORC1. This complex leads to the dissociation of Raptor and loss of contact between mTORC1 and its substrates.

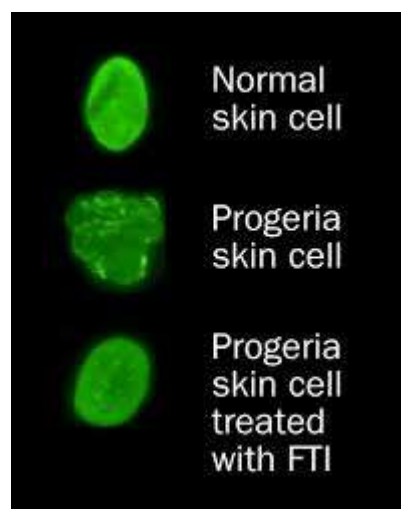
The discovery of rapamycin immediately raised great interest in the scientific community for its numerous properties, e.g. as a powerful antibiotic, antiproliferative and immunosuppressant. In 1991, rapamycin was approved by the US Food and Drug Administration (FDA) for the prophylaxis of renal transplant rejection and as a chemotherapeutic agent against renal carcinoma. Moreover, rapamycin has been used to inhibit restenosis after the implantation of stents during coronary angioplasty.

Rapalogs -

The limitations in the solubility and pharmacokinetic properties of rapamycin led to the commercial development of new mTOR inhibitors, such as semi-synthetic rapamycin analogues, named rapalogs or active site inhibitors. Rapalogs have an improved bioavailability when compared with rapamycin, and include CCI-779 (temsirolimus or torisel), RAD001 (everolimus) and AP23573 (ridaforolimus), which have been, and continue to be, tested in a wide range of clinical trials. The orally available RAD001 is more efficacious than rapamycin.

Resveratrol -

Resveratrol is a natural polyphenol that shows numerous beneficial effects, acting as an antioxidant, anti-inflammatory and anticancer drug. Moreover, it seems to have protective effects against a number of cardiovascular and neurodegenerative diseases. It has been reported that resveratrol can inhibit mTORC1.



Metformin -

There is a growing body of evidence that metformin inhibits mTORC1 through a different mechanism, by activating AMPK. AMPK, in turn, blocks mTORC1 [39] regulating its related GTP binding (Rag) GTPases and indirectly activating regulated in development and DNA damage responses 1 (REDD1), a mTOR inhibitor that promotes TSC2 activity. Progerin accumulation is reduced by mevinolin treatment. In the attempt to destabilize progerin, we used mevinolin to obtain defarnesylation. WB analysis of wildtype pre lamin A caused by mevinolin in all the examined cell lines, a decrease in the amount of progerin was observed in HGPS lysates. The lamin A level was slightly reduced by mevinolin treatment, while amounts of lamin C and emerin were not affected.

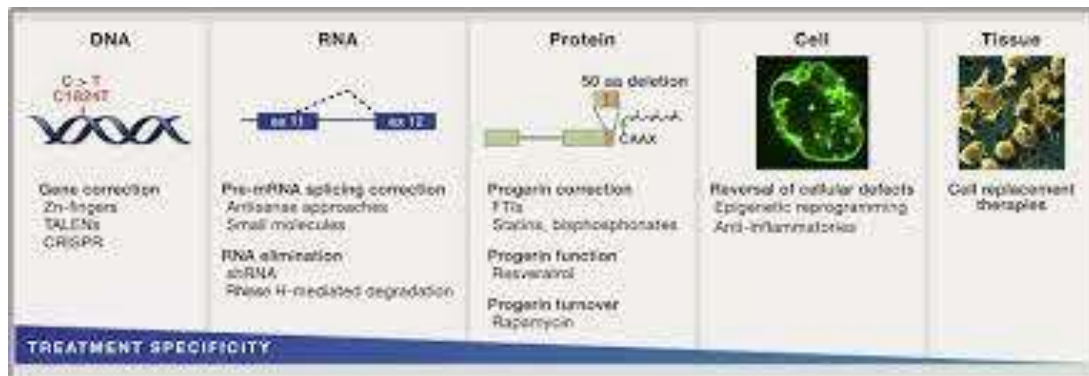
Heterochromatin organization in HGPS nuclei is improved by mevinolin/TSA treatment.

By Mevinolin treatment of HGPS fibroblasts apparently failed to improve nuclear shape abnormalities. TSA alone did not cause detectable changes in chromatin organization in control or in HGPS cells. Nuclear shape was improved after the combined treatment with mevinolin and TSA. Ribonucleoprotein levels are reduced in HGPS cells and restored by mevinolin/TSA treatment

We sought to determine if the increased availability of dispersed chromatin could affect the transcriptional activity of HGPS nuclei. The amount of incorporated BrU was reduced in enlarged HGPS nuclei showing major nuclear lamina defects and BrU- containing transcripts were distributed in the nucleus with a non-uniform pattern. After treatment with mevinolin and TSA, BrU incorporation was comparable to controls in most HGPS nuclei, including some enlarged nuclei. Uniform BrU staining was observed in HGPS nuclei after mevinolin/TSA treatment.

Progeria as a Testbed for therapeutic strategies :-

The development of therapeutic strategies for HGPS benefited from the confluence of gene discovery and extensive prior knowledge of lamin A function at the time of the gene discovery. This made several therapeutic strategies immediately apparent. Remarkably, the time from gene discovery to the first human therapeutic trial for HGPS was just 5 years (Kieran et al., . In the wake of initial therapeutic trials, exponential increases in our understanding of the disease mechanisms combined with technological advances have broadened the scope of both the potential therapeutic targets and approaches . All of the therapeutic strategies applied to HGPS are under consideration for many other diseases, and it is likely that experiences with HGPS will prove relevant to the larger medical community.



A Spectrum of Possible HGPS Therapies :-

HGPS is amenable to a wide spectrum of cutting-edge therapeutic strategies.

Drug Repurposing

Compared with developing any type of new medication, drug repurposing, which uses medications previously developed for other diseases, promises the shortest timeline from preclinical to clinical testing. Discovering that progerin is permanently farnesylated immediately opened the door for a candidate drug discovery approach using farnesyltransferase inhibitors (FTIs), which had previously been developed as potential anticancer drugs and had acceptable side effects in children. FTIs were quickly and successfully tested preclinically in cell culture, which showed improvement of disease symptoms upon FTI treatment. A prospective single-arm clinical trial was initiated in 2007 with a cohort of 26 HGPS patients between 3 and 16 years of age. Administration of the FTI lonafarnib for a minimum of 2 years yielded improvements in weight gain, vascular stiffness, and bone structure in some patients and provided evidence for decreased headaches and, though the extent of improvements varied among patients. Subsequent to initiation of the first clinical trial, it was reported that progerin was partially modified in cultured HGPS fibroblasts by geranylgeranylation after FTI treatment. This alternate modification could be blocked by statins and aminobisphosphonates that prevent the production of both farnesyl and geranylgeranyl precursors. This result offered one possible explanation for why FTI treatment only modestly lengthened lifespan in a mouse model (and prompted several currently ongoing therapeutic trials in which FTIs are combined with pravastatin (a statin) and zoledronic acid (an aminobisphosphonate). The development of

combination therapies reflects a potentially powerful iterative approach between basic and clinical sciences toward improving and optimizing therapeutic strategies.

The drug-repurposing approach for HGPS is still ongoing. One rationale is that treatments with putative prolongevity effects may also benefit children with HGPS. For example, the macrolide antibiotic rapamycin, which extends lifespan and improves stroke volume in several model organisms, including aging mice, has been shown to abolish nuclear structure defects and postpone senescence in HGPS fibroblasts in cell culture by enhancing progerin clearance through autophagy. Another compound of interest is resveratrol, a SIRT1 activator that interacts with lamin A. In the presence of progerin, SIRT1 exhibits reduced association with the nuclear matrix and decreased deacetylase activity, leading to rapid depletion of adult stem cells in an HGPS model mouse. Treatment with resveratrol improved cellular phenotypes and extended lifespan in this mouse model. Other repurposed drug candidates are likely to emerge, for example, non-steroidal antiinflammatory drugs, which may be useful for blocking the NF- κ B-signaling hyperactivation observed in progeroid cells and mouse models.

New Drug Discovery Strategies :-

The HGPS etiology offers several points of entry for drug discovery. One potential avenue is the identification of small molecular inhibitors of the aberrant pre-mRNA splicing event in HGPS. But this is a challenging undertaking, as no specifically acting small molecular regulators of pre-mRNA splicing have ever been reported. As a complementary approach, imaging-based high-content screens may be able to identify small molecules that prevent the formation, or promote the reversion, of HGPS cellular phenotypes. Aberrant nuclear morphology, DNA damage, or elimination of the progerin protein may serve as readouts for these cell-based approaches in drug discovery. HGPS patient-derived iPS cells should prove a particularly useful tool for such screens. New candidate molecules from several such screens are likely to be forthcoming shortly.

Similar to the farnesylation inhibitor treatment strategy, another potential treatment avenue is based on our understanding of lamin A posttranslational modifications. After farnesylation, the last three amino acids of prelamin A and progerin are cleaved, and the farnesylcysteine is methylated. Inhibition of the posttranslational methylation step was recently reported to improve HGPS cellular senescence in vitro and ameliorated disease and early death in a progeroid mouse model.

RNA Therapy :-

Because the HGPS mutation results from the activation of an alternative pre-mRNA splice site, HGPS is a prime candidate for an RNA therapy approach via inhibition or elimination of this site. Reversal of phenotype by inhibition of the altered splice site was first achieved in HGPS fibroblasts by treatment with a morpholino antisense oligonucleotide targeted to the activated splice site. This strategy was successfully applied to a knockin HGPS mouse model, resulting in improved body weight, extended lifespan, and correction of several mutant phenotypes. An alternative approach is to eliminate the progerin mRNA using siRNA-based methods. Although systemic delivery of oligonucleotides and siRNAs remains a challenge to these therapeutic approaches, the availability of an appropriate animal model, an extensively clinically characterized patient population, and a clearly defined primary target tissue (the vasculature) may make HGPS an attractive case study for the development of high-efficiency delivery methods for these types of agents.

Stem Cell Treatment -

Many of the alterations seen in HGPS are consistent with stem cell dysfunction; In vitro, progerin affects the multipotency and differentiation of human mesenchymal stem, and HGPS patient-derived iPS cells exhibit differentiation defects. Furthermore, in a HGPS-related cellular model, the proliferative potential of epidermal stem cells was reduced, and in an inducible HGPS mouse model that specifically expresses progerin in skin, the epidermal population of adult stem cells was depleted and wound healing impaired. This involvement of tissue-stem cells in the HGPS phenotype opens the possibility of cell-based replacement therapies using either matching wild-type cells or tissue-stem cells generated from genetically corrected HGPS iPS cells. Cell replacement approaches face many challenges, particularly in systemic diseases such as HGPS. However, the prominence of the vascular defects in HGPS may provide an interesting model system to explore the effectiveness of tissue-targeted approaches in systemic diseases.

Gene Therapy -

Approaches As the progerin protein acts in a dominant fashion and its effects cannot be compensated by introduction of wild-type lamin A, gene therapy for HGPS focuses on targeted gene correction. For example, zinc-finger, TALEN, or CRISPR-based approaches, in which the LMNA is repaired ex vivo and corrected cells are re-introduced into patients, is a possibility, albeit a technically challenging one. As proof of principle for the feasibility of this approach, correction of the genetic defect in HGPS patient-derived iPS cells and their subsequent differentiation has been achieved.

Challenge of clinical trials for rare diseases -

Rare diseases pose particular challenges in designing and executing clinical trials. Given that there are more than 6,800 rare diseases—about 80% of them with a genetic basis—the lessons learned during the rapid journey in HGPS from gene identification to clinical trial may be of value to other disease populations. The very limited pool of patients with HGPS required worldwide recruitment and organized communication with patient families and their

physicians through programs such as international patient registries, diagnostics programs, and continued outreach to the patient community. For optimal trial execution, these processes must precede clinical trials by several years. For HGPS, this recruitment was achieved through a patient advocacy organization (The Progeria Research Foundation), and the first clinical trial was fully enrolled in under 4 months. Hospital-based centers of excellence with similar programs can also be useful for recruiting patients to trials.

Due in part to the 100% fatality rate in HGPS and in part to the extremely small subject numbers (26 in the published clinical trial), all human trials to date have used open label design with no placebo control groups. In order to assess drug efficacy, primary outcome measures have relied upon a change in individual patient status using each patient as his or her own control. Designing appropriate outcome measures required intensive and ongoing natural history studies to establish robust baseline values for each clinical parameter in each individual patient. For any disease, investment into natural history clinical trials, with the aim of identifying longitudinal trends in disease-relevant and consistently evaluable clinical abnormalities for use as treatment trial outcome measures, is invaluable. In addition, natural history studies are remarkably insightful and powerful in uncovering disease characteristics. For example, some of the most relevant vascular defects in HGPS were discovered during baseline studies conducted as part of the first clinical trial, which precluded their inclusion as primary outcome measures for trial drug efficacy but led the way for improving detection of therapeutic efficacy in future trials. The constraints and approaches seen in the HGPS trials are not unlike those in oncology trials for rare, fatal pediatric cancers, wherein similar challenges apply and similar trial designs are used.

Future trials will need to grapple with how to reliably measure changes in disease status in the face of combination therapies whose implementation will also further amplify the challenge of recruiting sufficiently large patient populations for each treatment combination. Although treatment outcomes have been published for HGPS monotherapy using lonafarnib, its effects on patient morbidity and mortality are not yet known and will require longer-term patient exposure. Given this, an important issue at hand is whether it will be ethical and statistically viable to conduct future trials using a control arm with farnesylation inhibitors and a treatment arm with farnesylation inhibitors plus a new treatment of interest.

Regulatory approval based on uncontrolled or small trials is a huge challenge, as the U.S. Food and Drug Administration (FDA) is responsible for evaluating safety and efficacy and for weighing the risk-to-benefit ratio with much less data than what is supplied for common diseases. Rare disease applications are the fastest growing area of pharmaceutical and biotechnical development. Unlike only 5 years ago, today there is an acute awareness of rare diseases within the FDA, which has identified the rare disease space as a priority area. As a result, the FDA has proactively created the Center for Drug Evaluation and Research specifically for Rare Diseases Drug Development. In addition, the FDA and European Medicines Agency Orphan Drug status is designed to fast track what is usually a very long process, without compromising the quality of the review process. Although increasing patient numbers may not be an option, there is now a regulatory body that can be consulted specifically on recommendations for rare disease treatment trials.

Scope for future research :-

Progeria (or HGPS) is a rare syndrome which makes it difficult to study. Due to the efforts of parents of the affected children, a few research groups and the Progeria Research Foundation (PRF), the awareness of this syndrome has increased significantly. Research has also proposed probable markers for this syndrome. For example, elevated HA levels have been suggested as specific marker for HGPS, but other studies have nullified this by reporting that urinary and serum levels of HA in HGPS patients are comparable with controls. Gordon and co-workers did a thorough analysis of the serum and urinary hyaluronidases by both quantitative (using ELISA) and qualitative (using a gel detection method) methods and contravened the use of HA as a marker for HGPS. Hence, the search for an accessible and definite kind of diagnostic marker is still on. The role of GH/IGF-1 axis in determining longevity has long been known. A study has shown that DNA damage results in suppression of the GH/IGF-1 axis which in turn leads to remarkable progeroid symptoms. More research on the causes and patterns of DNA damage in HGPS and ageing may provide some useful links between ageing and PS(s). The positive or negative interactions between the LMNA gene and other genes controlling ageing and longevity can be studied in appropriate animal models for better understanding of the pathogenesis and progression of HGPS. The PRF has 121 cell lines in their Cell and Tissue Bank, which are available on request for research purposes. A clear perception of the mechanism of pathogenesis of HGPS and other PSs would be helpful in understanding the abnormal conditions in the diverse branches of basic and applied life sciences like molecular biology, basic cellular senescence phenomenon, mitochondrial physiology, oncology, functional genomics and proteomics, dermatology especially dermal physiology, stem-cell biology, and many other degenerative disorders regarding which our knowledge is still meager. Thus, discovery of a cure for PS(s) would not only help the affected children but also a large number of patients suffering from cardiovascular diseases, stroke, cancer, etc.

Proteins linked to HGPS are suspected to play a pivotal role in the ageing process and this could be one of the reasons responsible for making these children predisposed to premature, progressive heart disease. When factors like IGF-1 signaling and functional cascade of events (of hormones) are checked in the prevalent and existing models of ageing and longevity (diet restriction), it has been observed that there is a significant shift from the normal parameters. This shift can be due to pituitary or any organ related faults, defect in the micronutrient (like vitamin D, etc.) metabolism, abnormal protein glycation, disturbed antioxidant status, to any other physiological process. It has been observed that WNIN/Ob (Wistar of National Institute of Nutrition obese rat) obese rats exhibits an unusual premature aging, develop various tumours, and have other immune response deficits. These kinds of animal models should be checked for their genomic, proteomic and biochemical status to look into the details of the common or shared and probably faulty pathways.

References :-

-
1. Kamenisch Y, Berneburg M. Progeroid syndromes and UV-induced oxidative DNA damage. *J Investig Dermatol Symp Proc.* 2009;14:8–14.

2. Progeria Research Foundation (PRF) webpage. [accessed on May 17, 2014]. Available from: .
3. Pereira S, Bourgeois P, Navarro C, Esteves-Vieira V, Cau P, De Sandre-Giovannoli A, et al. HGPS and related premature aging disorders: from genomic identification to the first therapeutic approaches. *Am J Med Genet A*. 2006;140:2603–24
4. Hennekam RC. Hutchinson-Gilford progeria syndrome: review of the phenotype. *Am J Med Genet A*. 2006;140:2603–24
5. Shalev SA, De Sandre-Giovannoli A, Shani AA, Levy N. An association of Hutchinson-Gilford progeria and malignancy. *Am J Med Genet A*. 2007;143:1821–6.
6. Yu CE, Oshima J, Fu YH, Wijsman EM, Hisama F, Alisch R, et al. Positional cloning of the Werner's syndrome gene. *Science*. 1996;272:258–62.
7. Eriksson M, Brown WT, Gordon LB, Glynn MW, Singer J, Scott L, et al. Recurrent de novo point mutations in lamin A cause Hutchinson-Gilford progeria syndrome. *Nature*. 2003;423:293–8.
8. Espandar R, Eraghi AS, Mardookhpour S. Simultaneous shoulder and hip dislocation in a 12-year-old girl with Hutchinson-Gilford progeria syndrome. *Acta Med Iran*. 2012;50:439–43.
9. Merideth MA, Gordon LB, Clauss S, Sachdev V, Smith AC, Perry MB, et al. Phenotype and course of Hutchinson-Gilford progeria syndrome. *N Engl J Med*. 2008;358:592–604.
10. Rastogi R, Chander Mohan SM. Progeria syndrome: a case report. *Indian J Orthop*. 2008;42:97–9.
11. Goldman RD, Shumaker DK, Erdos MR, Eriksson M, Goldman AE, Gordon LB, Gruenbaum Y, Khuon S, Mendez M, Varga R, and Collins FS (2004). Accumulation of mutant lamin A causes progressive changes in nuclear architecture in Hutchinson-Gilford progeria syndrome. *Proc. Natl. Acad. Sci. USA* 101, 8963–8968. Gordon LB (2013). PRF By The Numbers (The Progeria Research Foundation). .
12. Gordon LB, Harten IA, Patti ME, and Lichtenstein AH (2005). Reduced adiponectin and HDL cholesterol without elevated C-reactive protein: clues to the biology of premature atherosclerosis in Hutchinson-Gilford Progeria Syndrome. *J. Pediatr*. 146, 336–341.
13. Gordon CM, Gordon LB, Snyder BD, Nazarian A, Quinn N, Huh S, Giobbie-Hurder A, Neuberger D, Cleveland R, Kleinman M, et al. (2011). Hutchinson-Gilford progeria is a skeletal dysplasia. *J. Bone Miner. Res*. 26, 1670–1679.
14. Gordon LB, Kleinman ME, Miller DT, Neuberger DS, Giobbie-Hurder A, Gerhard-Herman M, Smoot LB, Gordon CM, Cleveland R, Snyder BD, et al. (2012). Clinical trial of a farnesyltransferase inhibitor in children with Hutchinson-Gilford progeria syndrome. *Proc. Natl. Acad. Sci. USA* 109, 16666–16671.
15. Halaschek-Wiener J, and Brooks-Wilson A (2007). Progeria of stem cells: stem cell exhaustion in Hutchinson-Gilford progeria syndrome. *J. Gerontol. A Biol. Sci. Med. Sci*. 62, 3–8.
16. Havelka GE, and Kibbe MR (2011). The vascular adventitia: its role in the arterial injury response. *Vasc. Endovascular Surg*. 45, 381–390.
17. Hisama FM, Lessel D, Leistritz D, Friedrich K, McBride KL, Pastore MT, Gottesman GS, Saha B, Martin GM, Kubisch C, and Oshima J (2011). Coronary artery disease in a Werner syndrome-like form of progeria characterized by low levels of progerin, a splice variant of lamin A. *Am. J. Med. Genet. A*. 155A, 3002–3006.
18. Huang S, Chen L, Libina N, Janes J, Martin GM, Campisi J, and Oshima J (2005). Correction of cellular phenotypes of Hutchinson-Gilford Progeria cells by RNA interference. *Hum. Genet*. 118, 444–450.
19. Hutchinson J (1886). Congenital absence of hair and mammary glands with atrophic condition of the skin and its appendages. *Med. Chir. Trans*. 69, 473–477.